September 12-14
2018
Les Comtes de Méan
Liège, Belgium

6th International Meeting on Aortic Diseases

New insights into an old problem CHU Liège, APF

www.chuliege-imaa.be

Critical aortic dissections: benefit of surgical creativity out of any guidelines.

Prof Parla ASTARCI

Head of Cardiovascular Department

Cliniques universitaires St-Luc

Brussels, Belgium

CHU de Liège

Disclosure of Interest

Consultant for Boston Scientific

Consultant for Endologic

Definition of an aortic dissection

Spliting of the aortic wall at the level of the media creating a ***False lumen*** separated from the ***True lumen*** by a ***Flap***

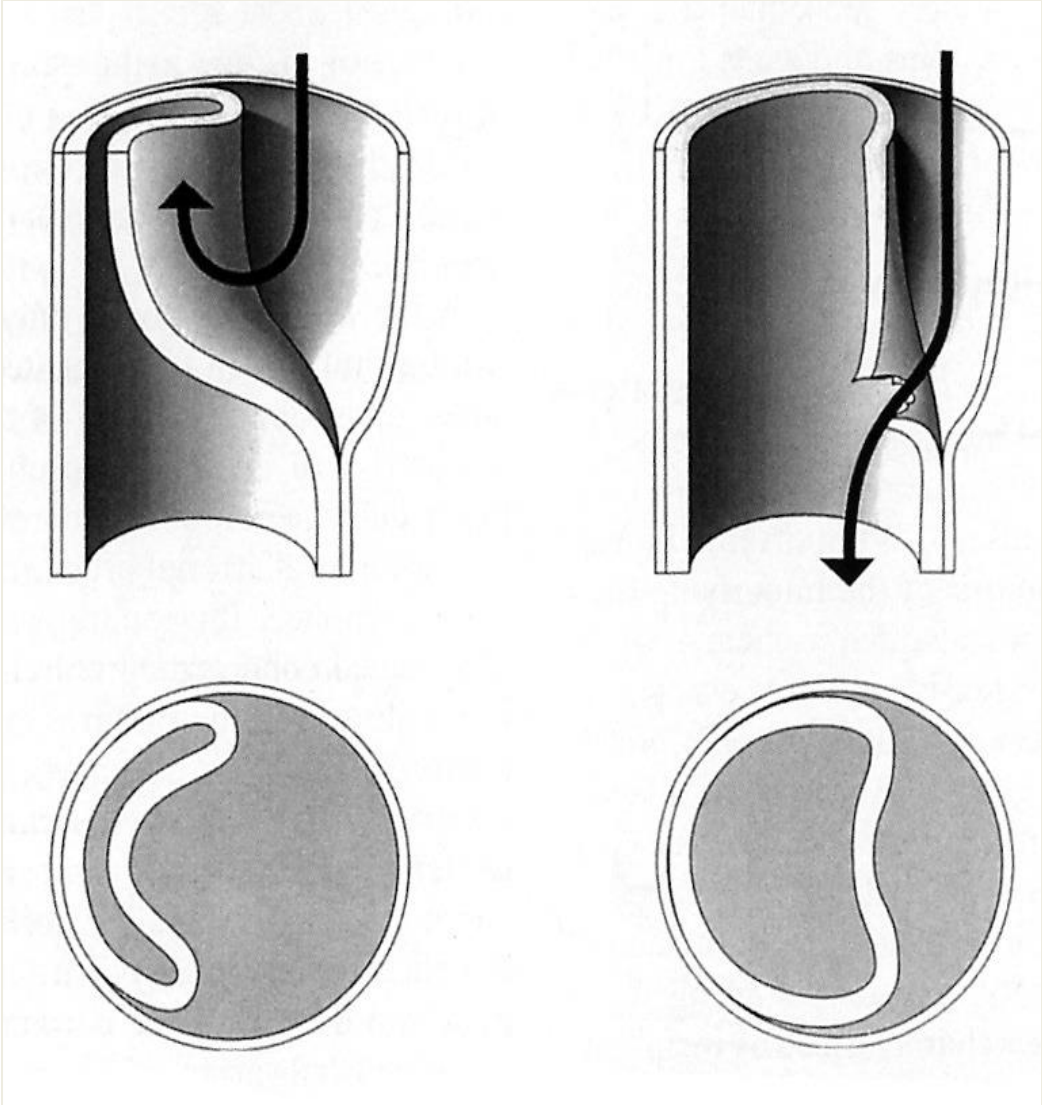

Dissection Classifications.

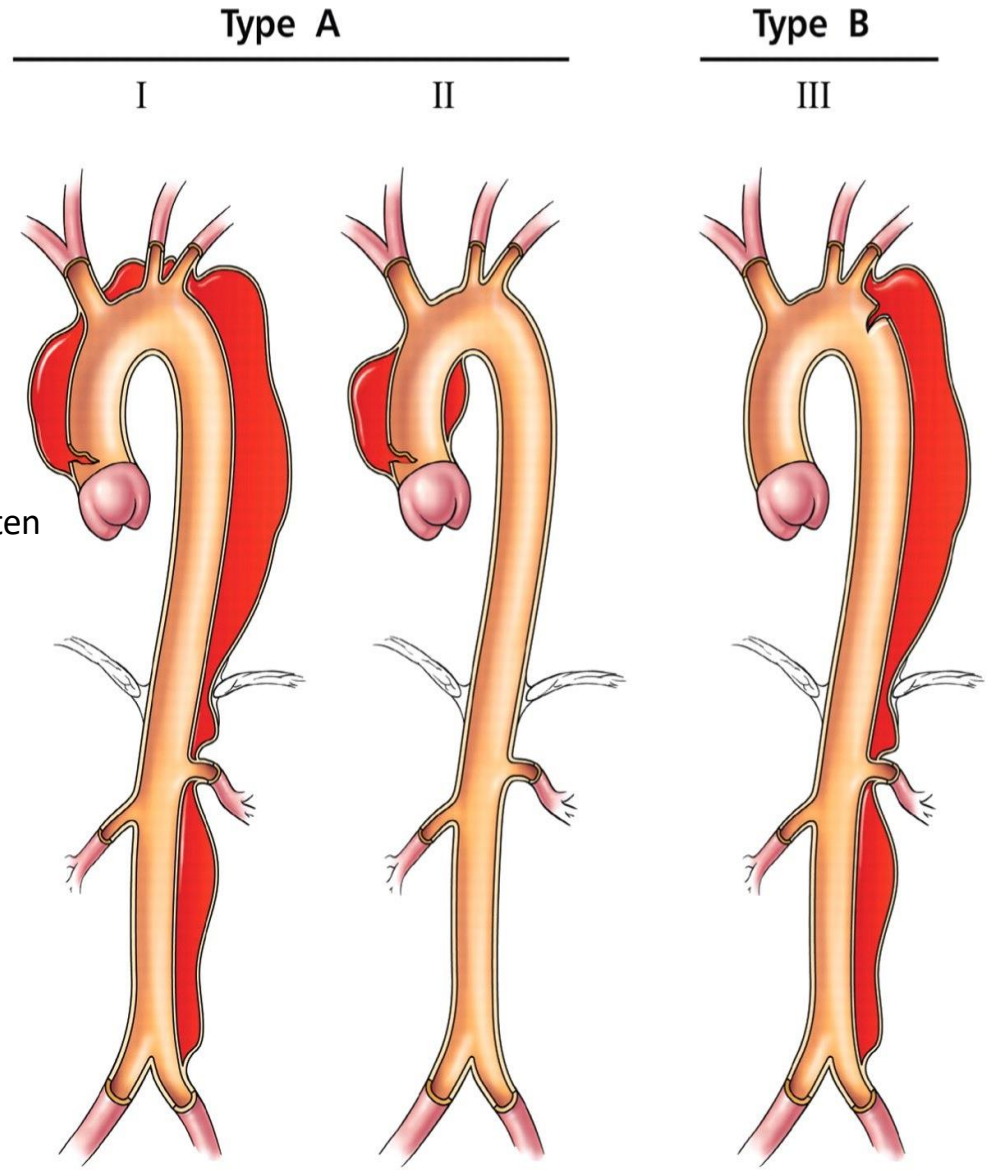

The DeBakey classification

- Type I: begins in asc. aorta at least to the aortic arch or beyond.
- Type II: dissections involve the ascending aorta only
- Type III: begin in the descending aorta, most often just distal to the left subclavian artery.

The Stanford classification

- Type A: ascending aorta
- Type B: do not involve ascending aorta.

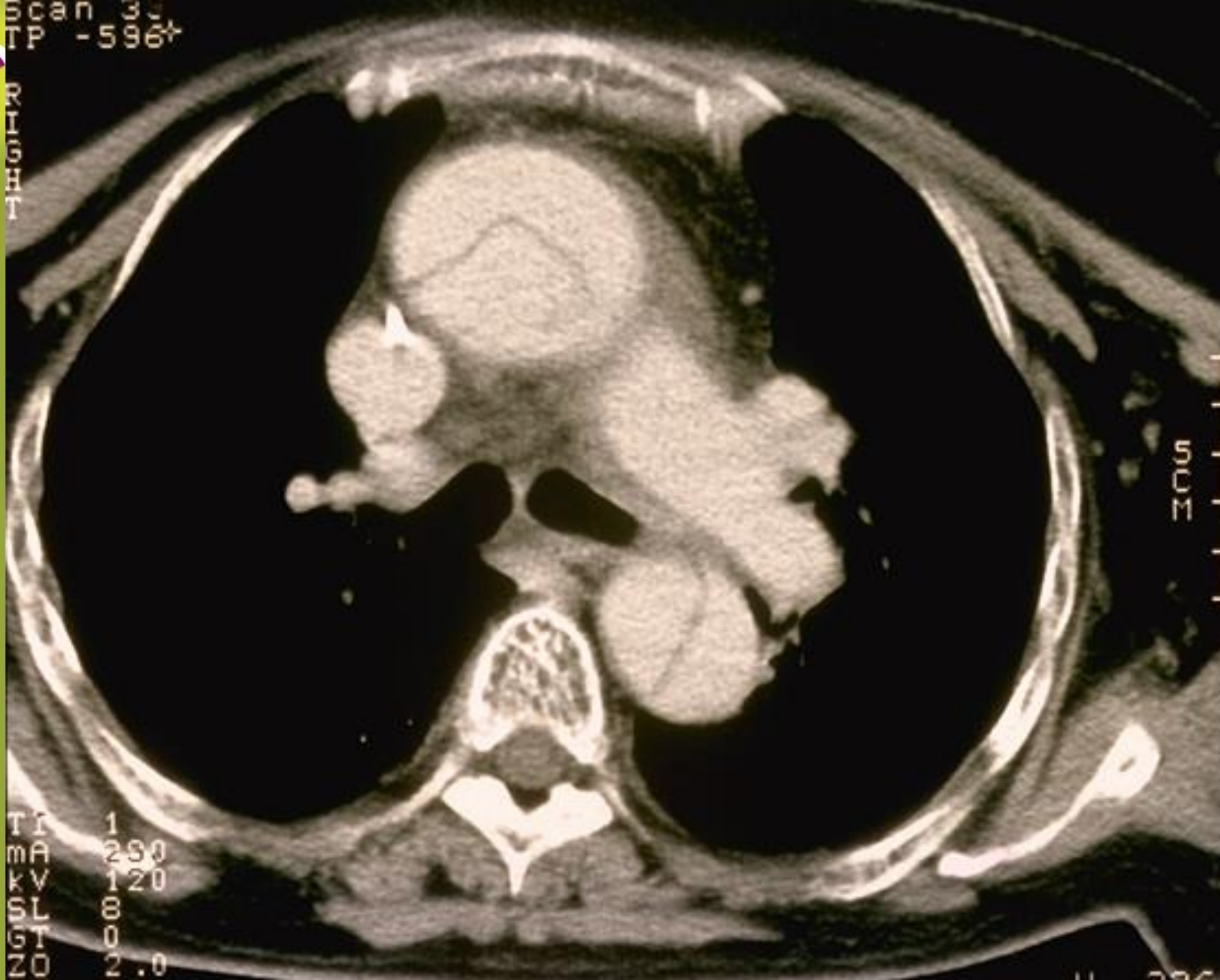
Scan 3
TP -596
RIGHT
5
CM
TI 1
mA 250
kV 120
SL 8
GT 0
ZO 2.0

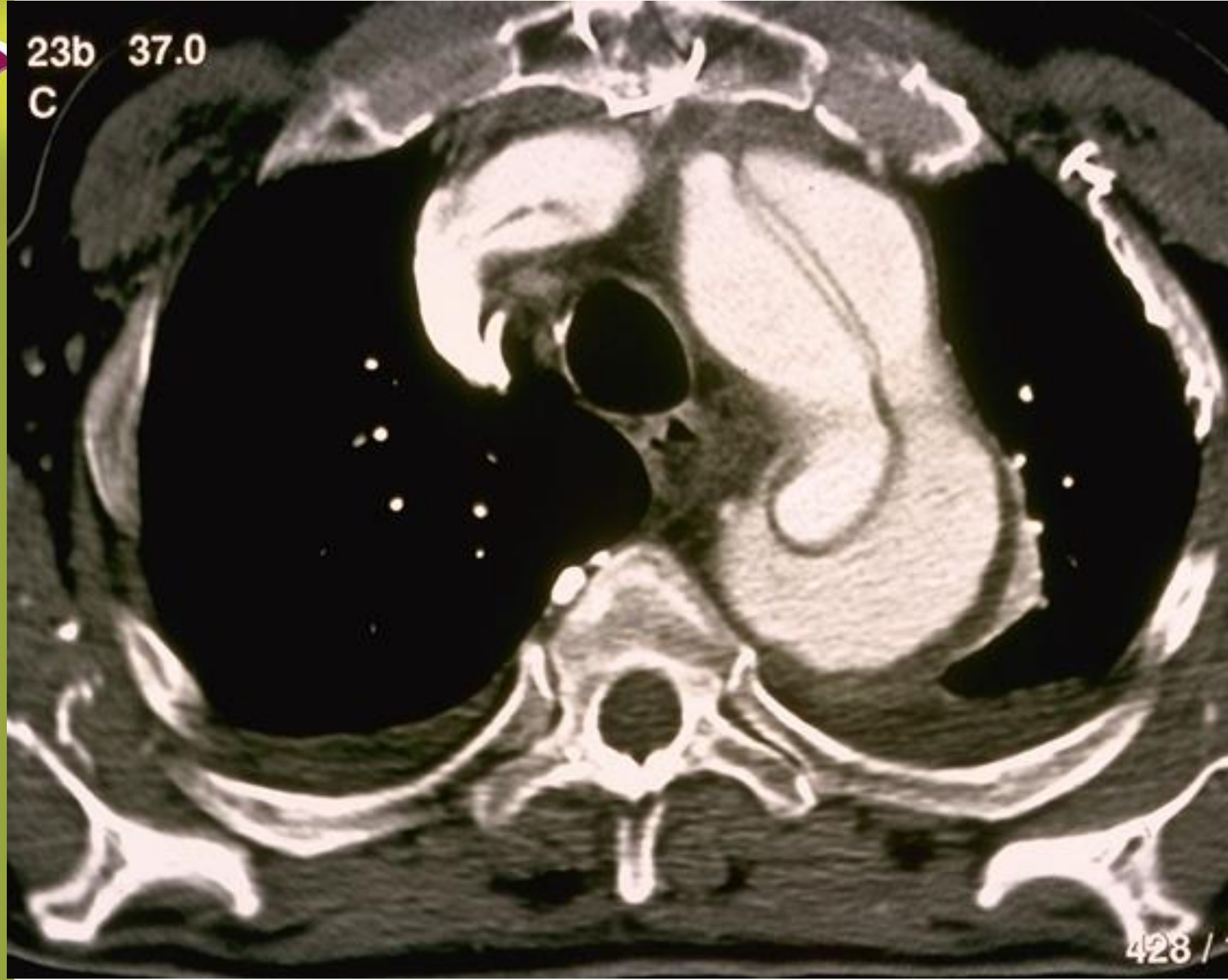
23b 37.0
C
428

When you open those patients…

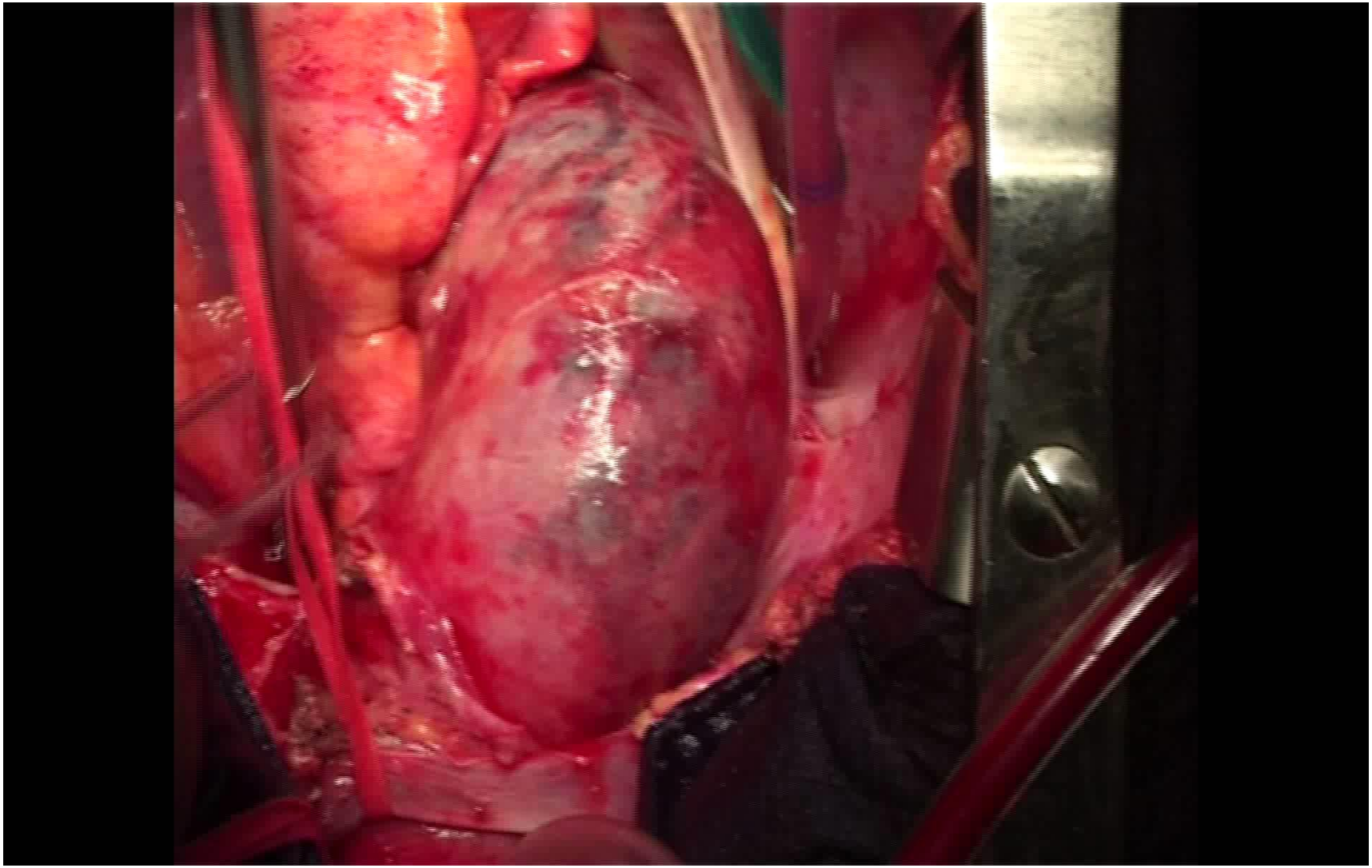

Hemi-arch reconstruction

Felt "neo-media" placed at the distal anastomosis during

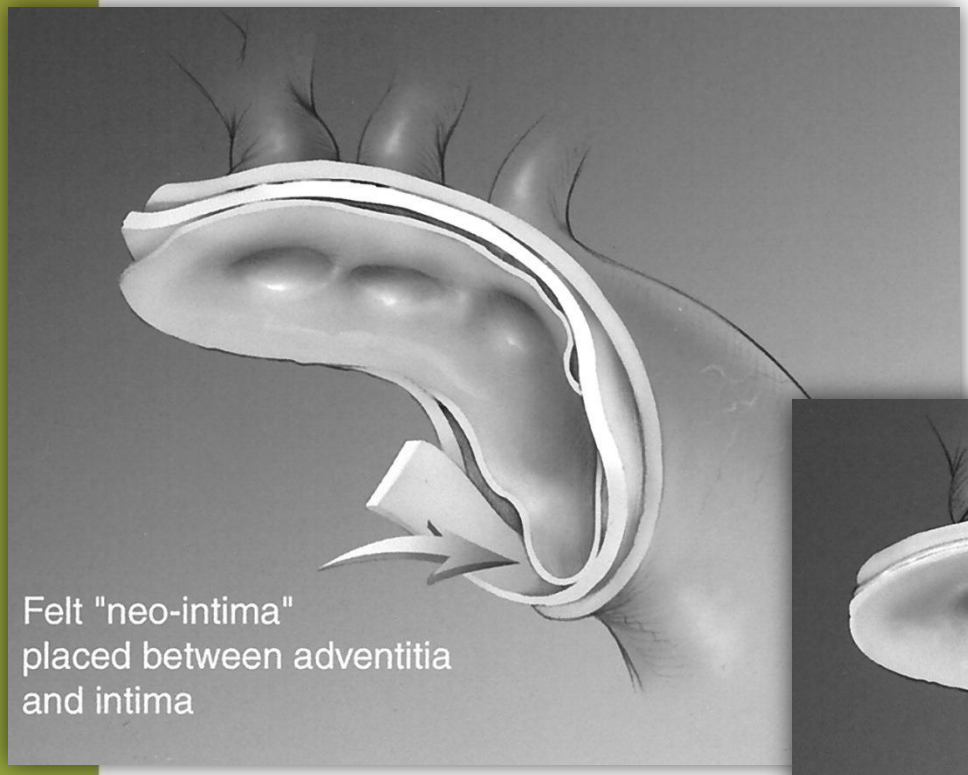

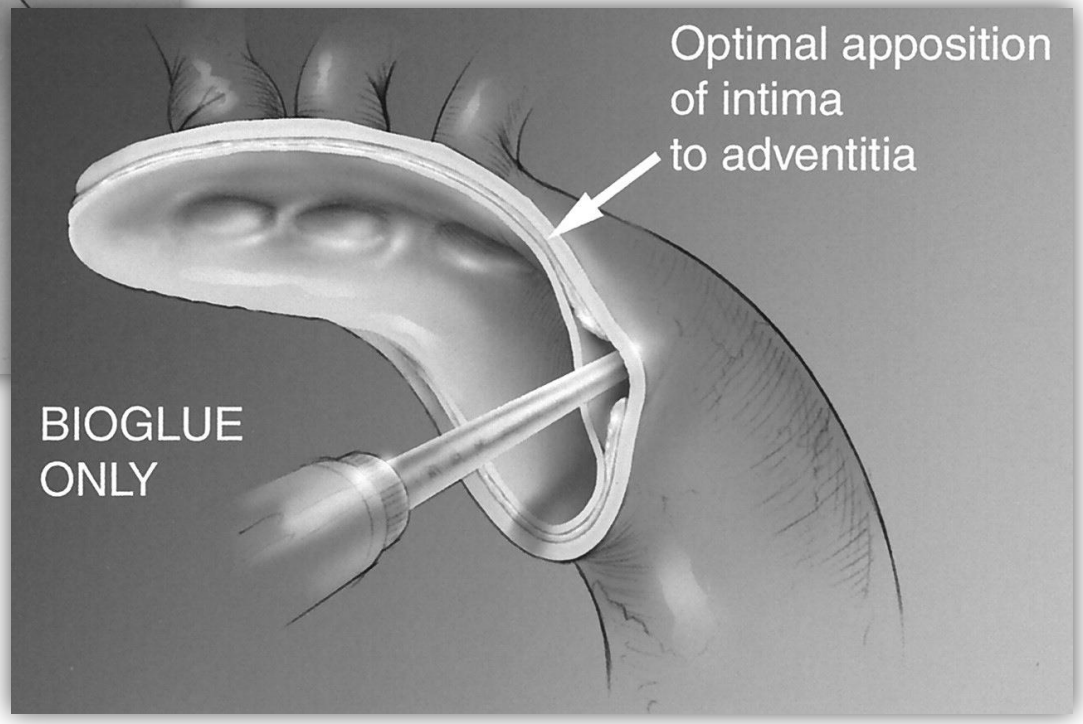

Full Arch reconstruction Surgical Hybrid Graft

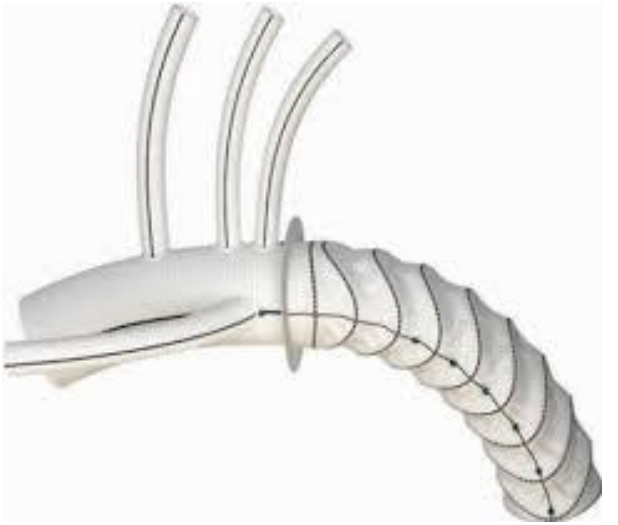

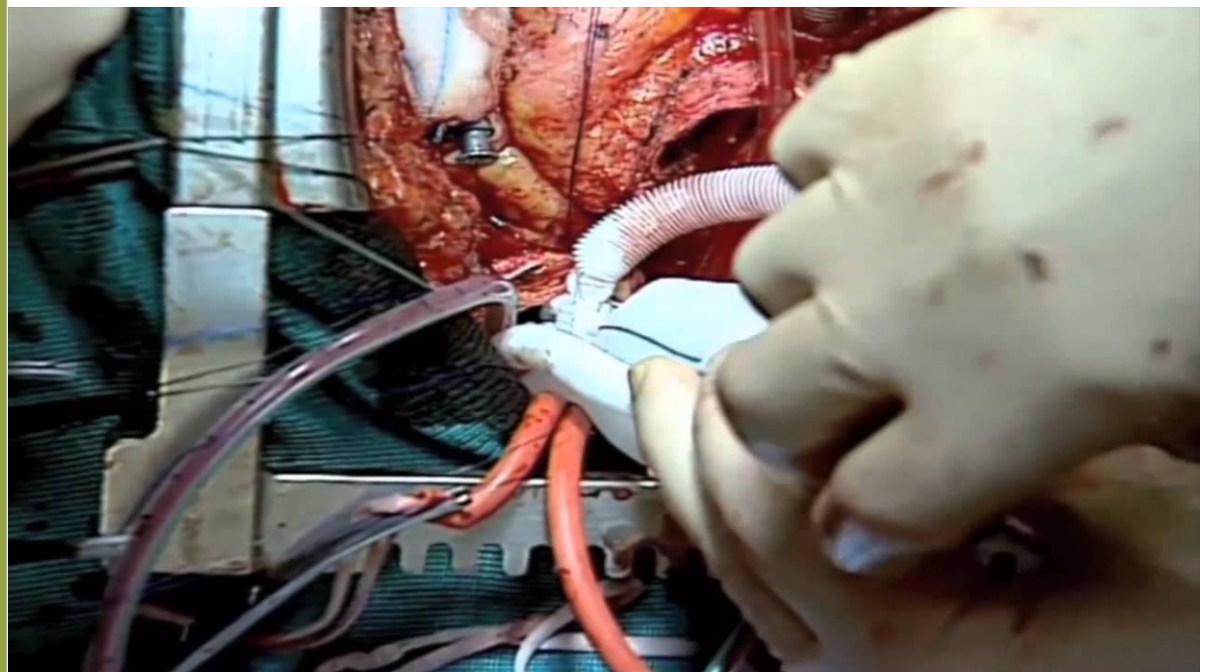

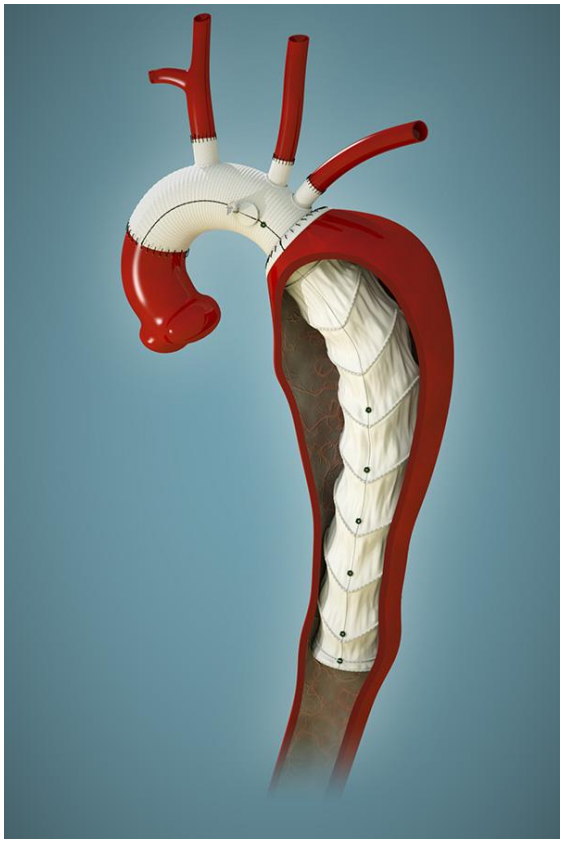

But all this is done under CPB AND HYPOTHERMIA

CRITICAL DISSECTION : CASE 1

Male
97 years old
Living with social help in his own house
73 Kg 174 cm BMI 24,1
GOOD general condition

Outpatient clinic October 2016
Symptomatic Aortic Valve stenosis

Cardiac evaluation

Symptomatic Aortic Valve stenosis

- Ao Valve Area :0,6 cm2
- Peak Gradient :80 mmHg
- Mean Gradient :55 mmHg
- EF :30-50%

Coronary angiography: LAD lesion

Operative risk evaluation

- Euroscore I : 21,48%
- Euroscore II : 6,57 %
- STS score : 5,37%

Geriatric evaluation

- ISAR :0/6
- SHERPA :5/11,5

- **Indication for TAVI**

Treatment Strategy

- STEP 1
  - November 2016
  - Direct stenting of the LAD with DES Biotronic Osiro 3,0x18,0 mm stent
- STEP 2
  - December 2016
  - Trans-Femoral Corevalve implantation

TAVI procedure

- Predilatation with Cristal Balloon 25 mm
- Corvalve deployment 31 mm
- Postdilatation with Cristal Balloon 28 mm

Preop Angio

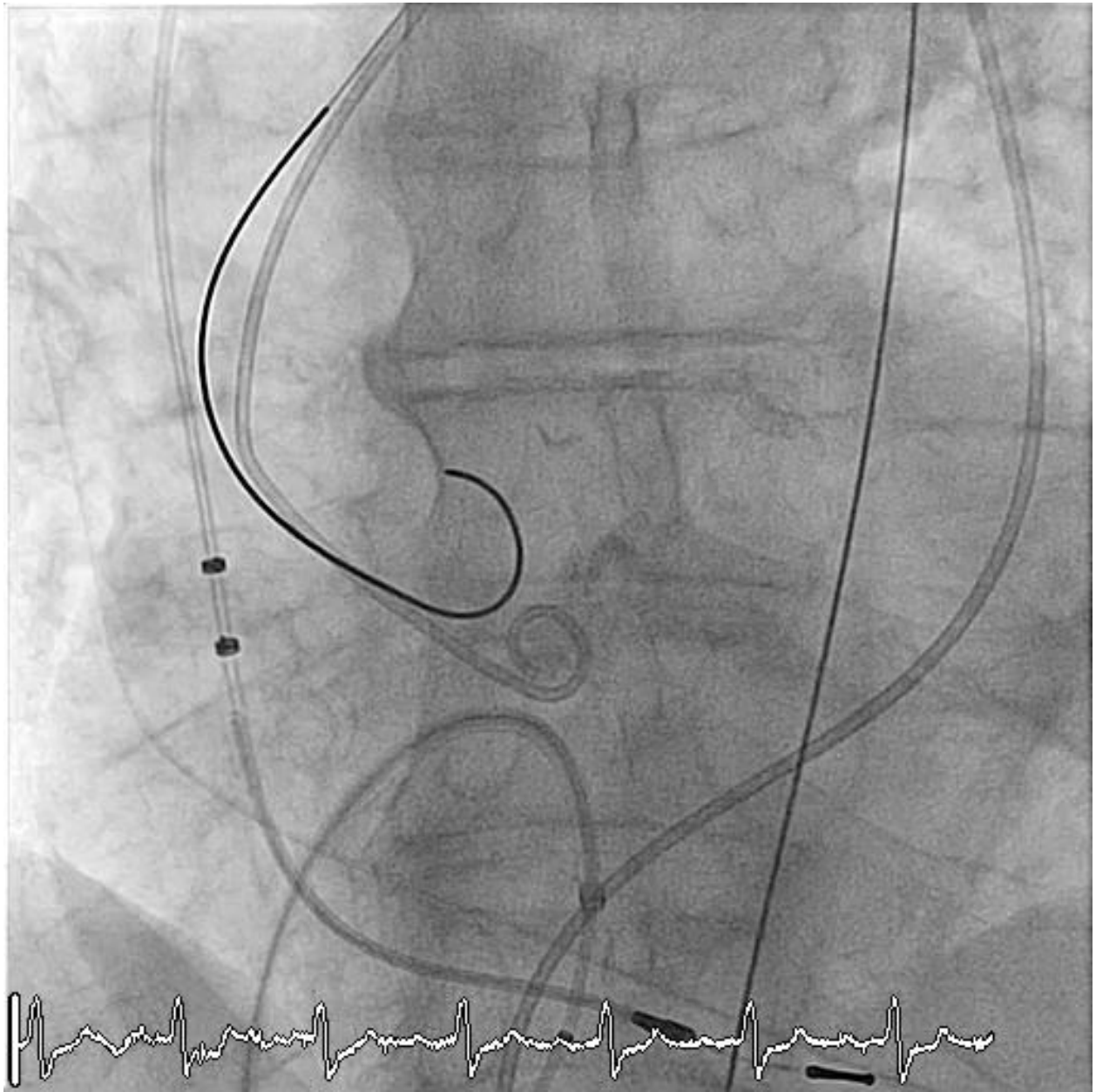

Pre-dilatation 25 mm balloon

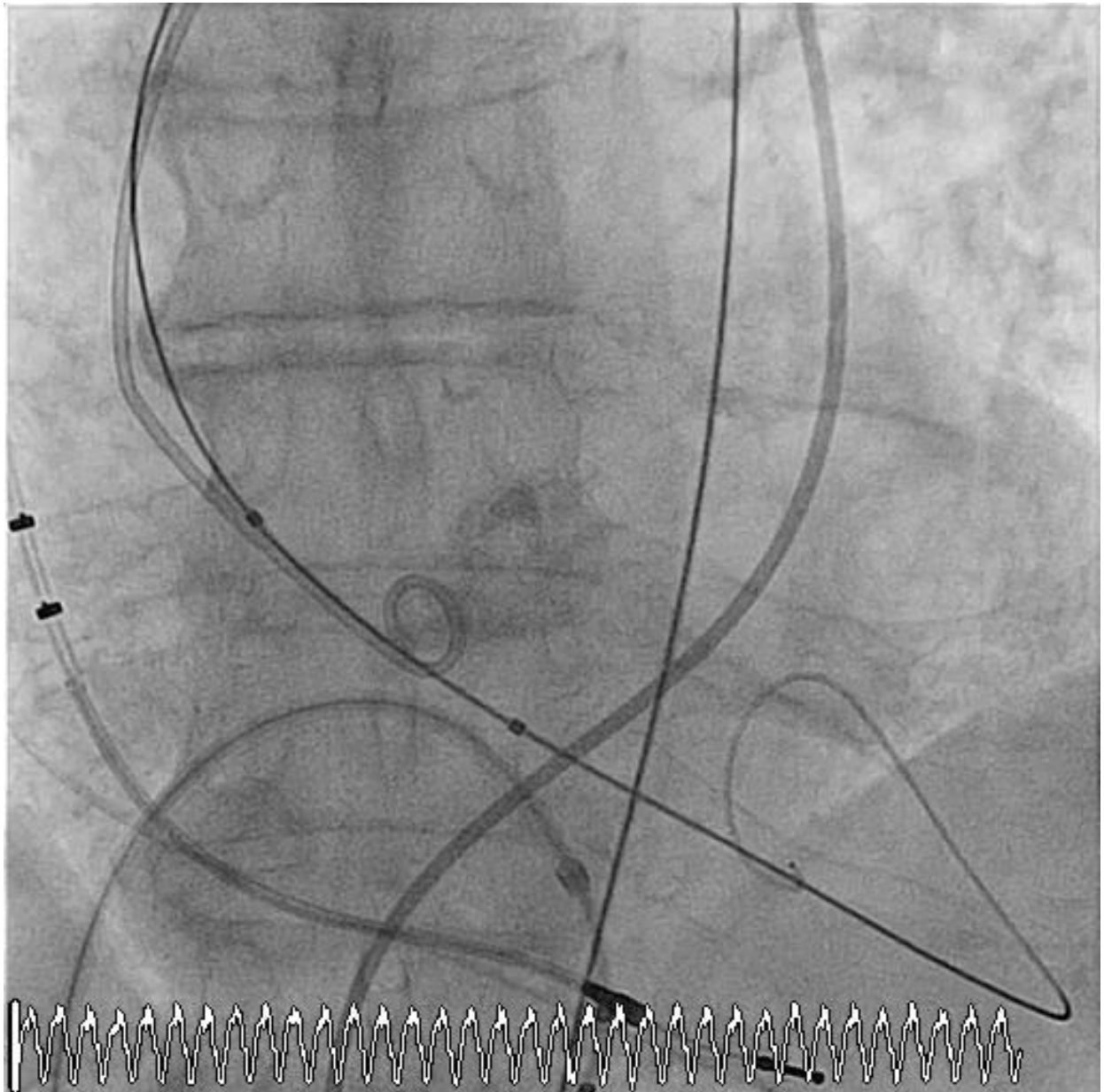

TAVI Corevalve 31 mm deployment

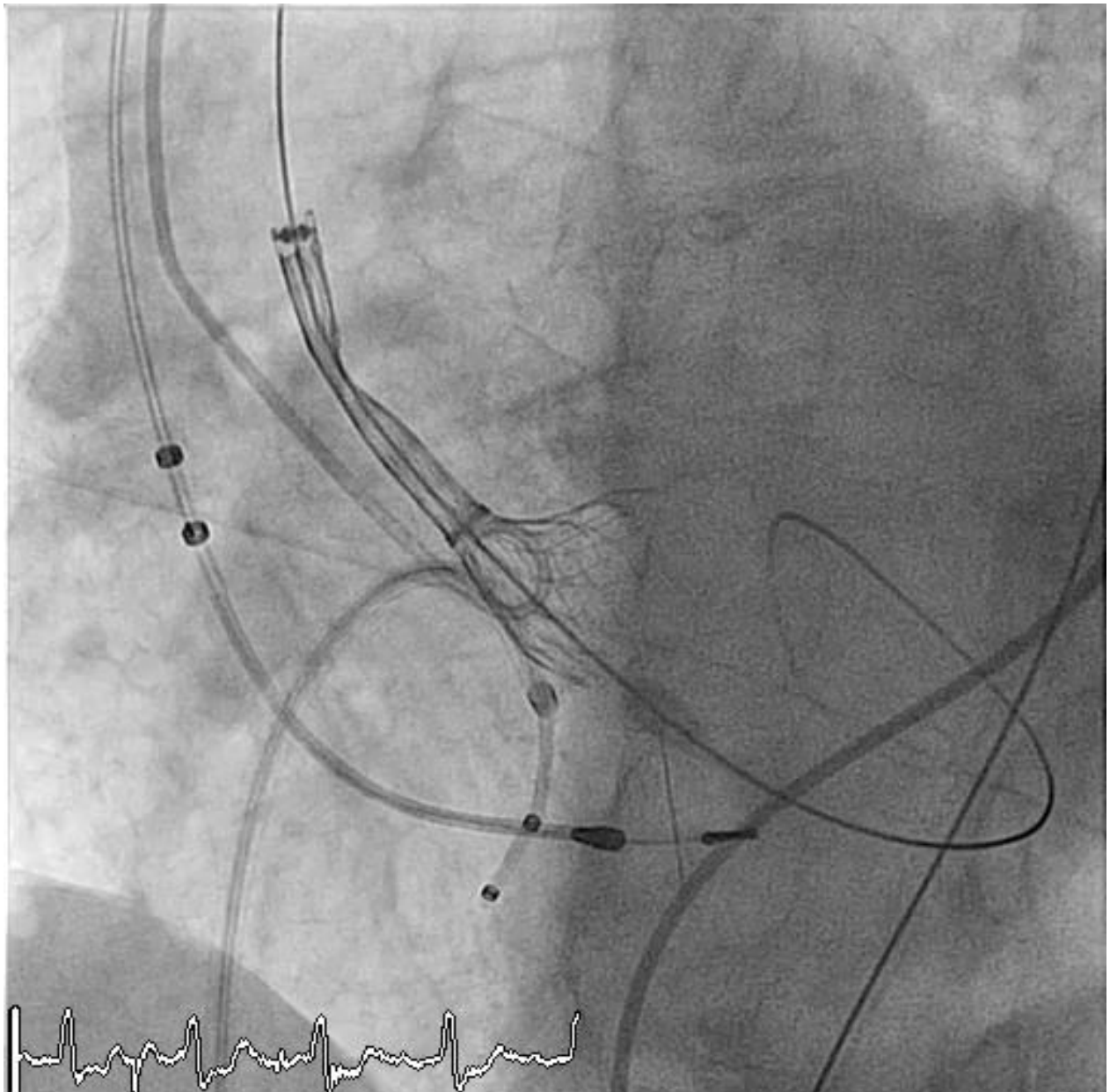

TAVI Corevalve 31 mm deployment

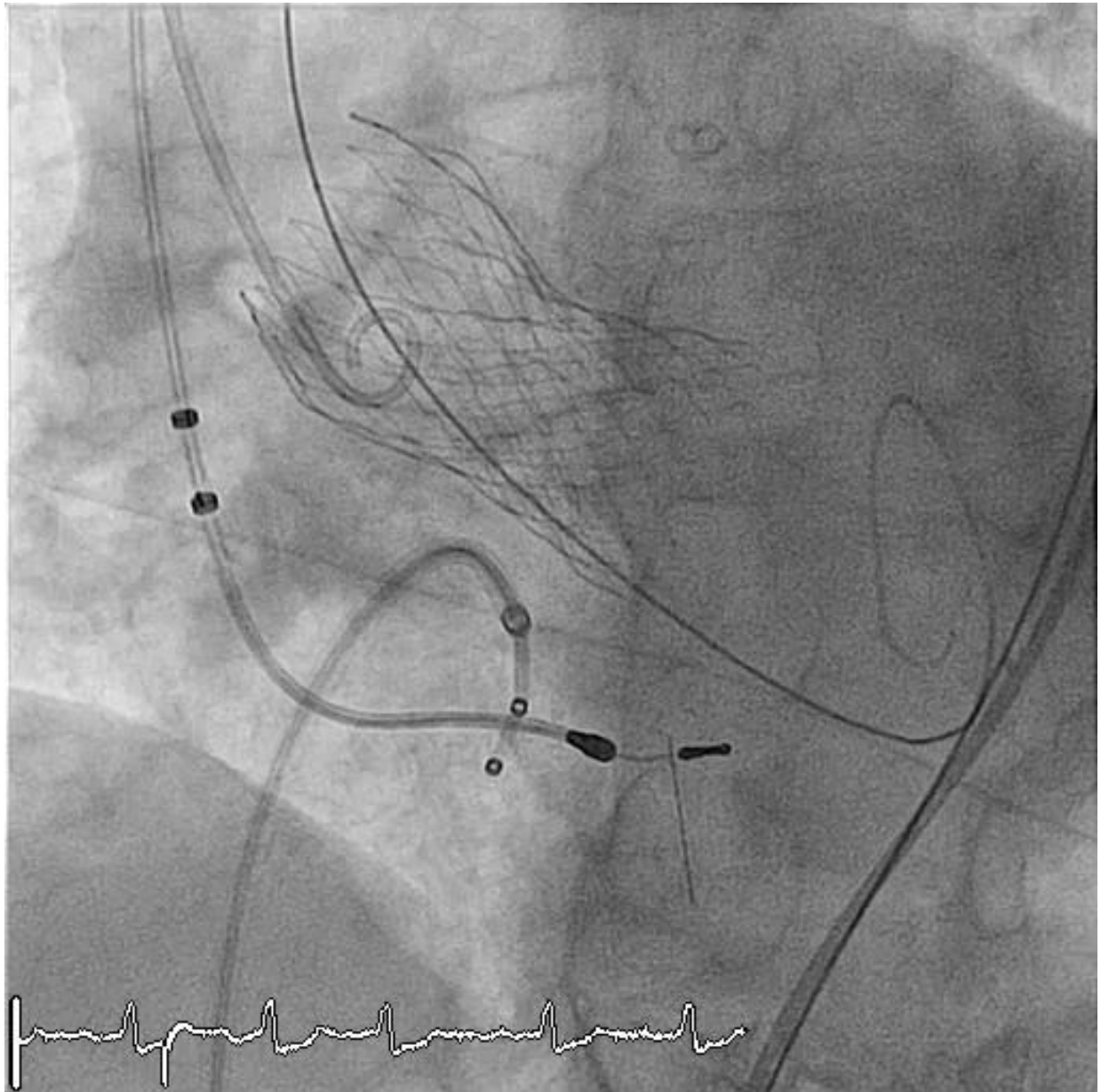

Result after post dilation

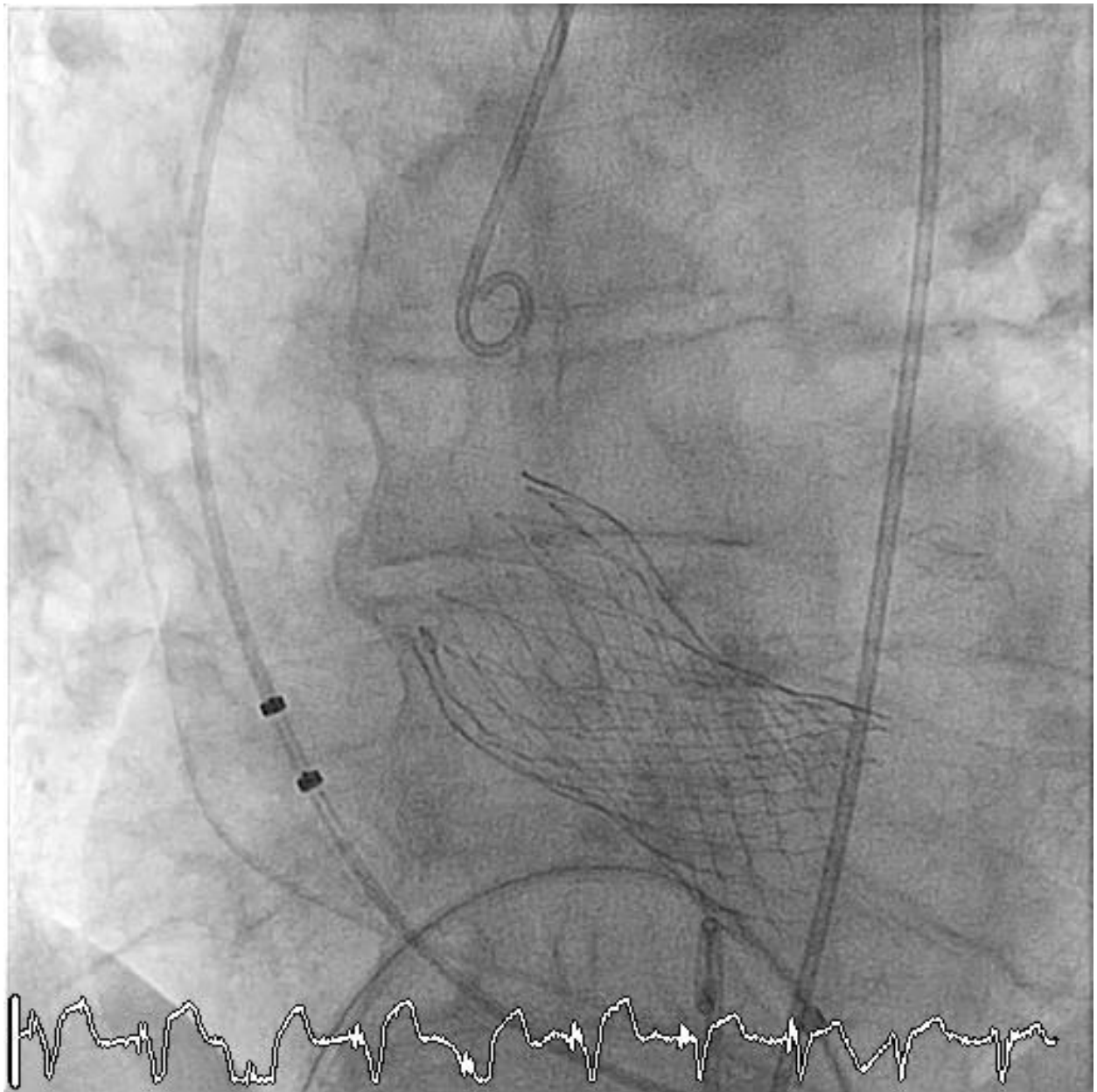

Type A dissection during TAVI, Which Treatment at 97 years ???

A. Surgical management of an acute type A dissection

   Sternotomy, CPB, Hypothermia, Ascending aorta replacement

B. Medical treatment

   ICU, hypotension, pain control and speak to family !

C. Coiling of the false lumen

D. Percutaneous stenting of the ascending aorta

Type A dissection during TAVI, Which Treatment at 97 years ???

A. Surgical management of an acute type A dissection

   Sternotomy, CPB, Hypothermia, Ascending aorta replacement

B. Medical treatment

   ICU, hypotension, pain control and speak to family !

C. Coiling of the false lumen

D. Percutaneous stenting of the ascending aorta

We decided to use
Zenith Dissection TX2 Bare Stent

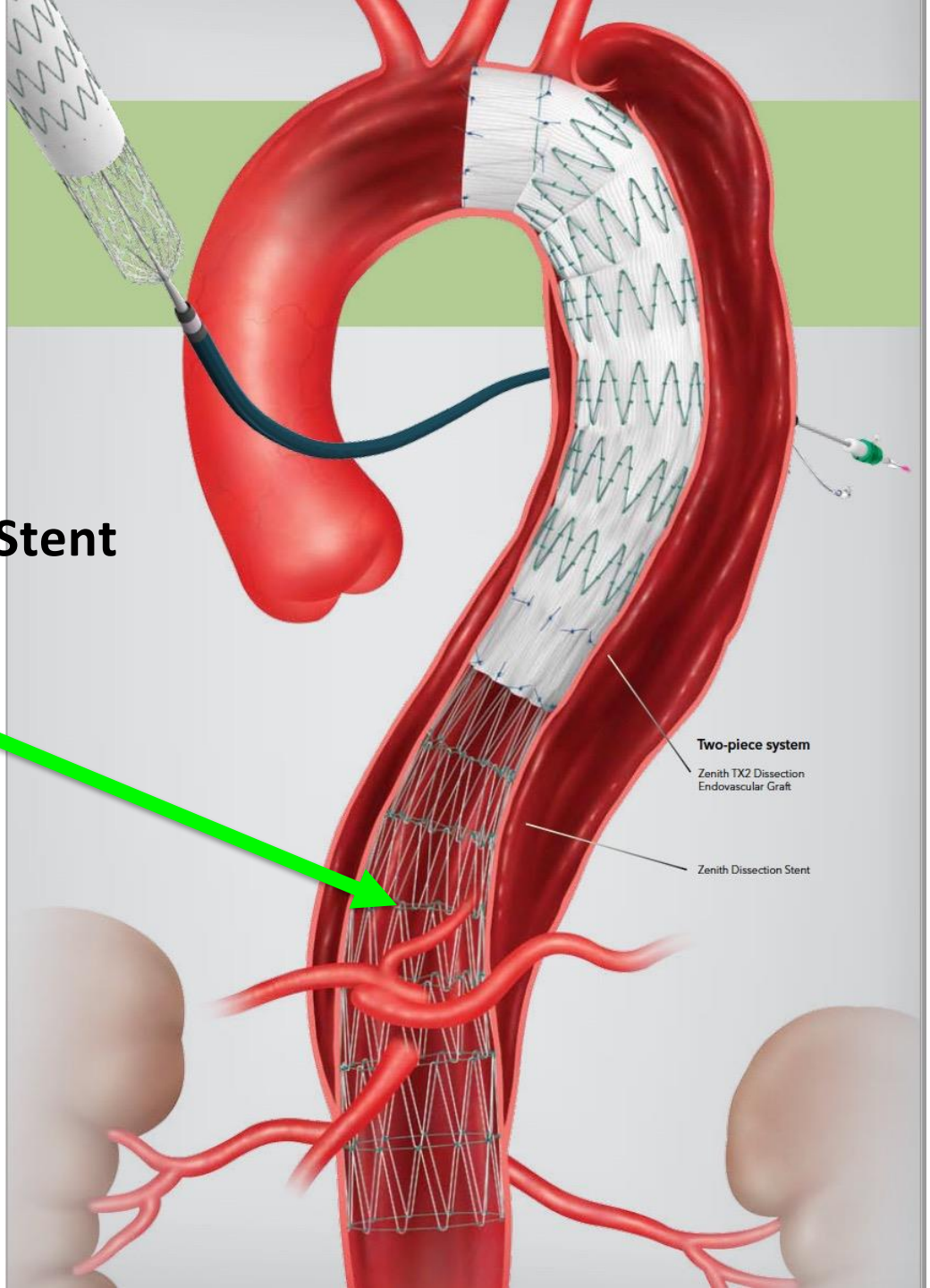

Percutaneous stenting of the ascending aorta

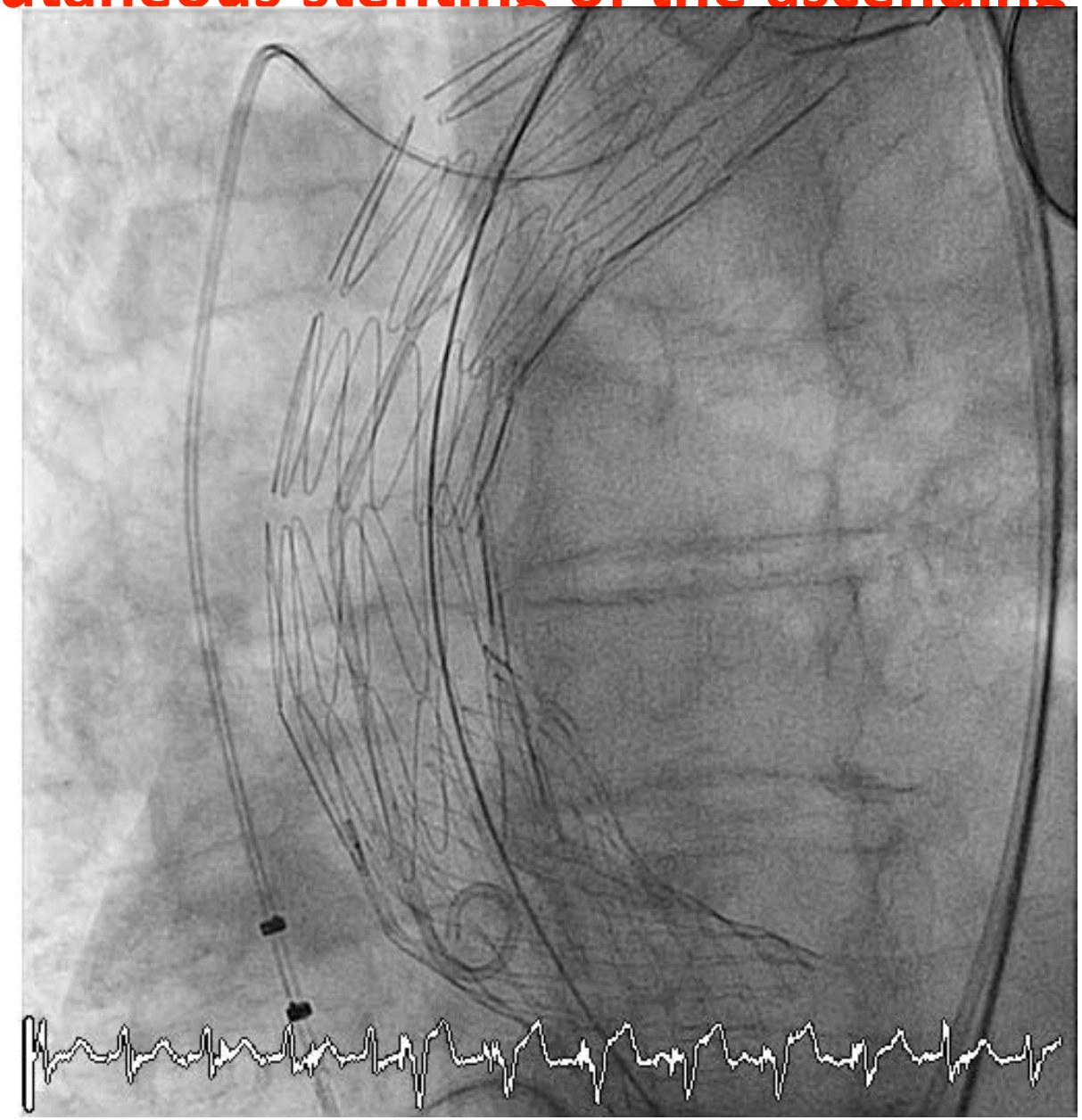

6 months follow-up (June 2017)

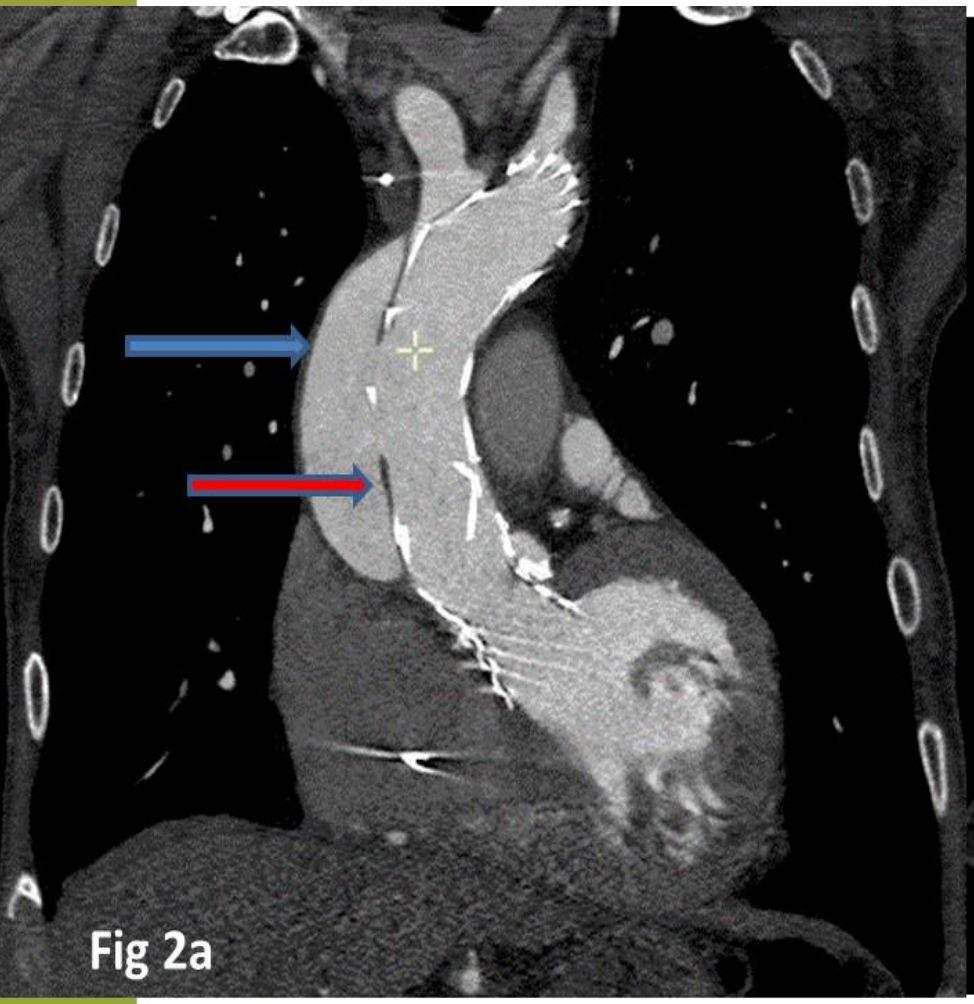

Fig 2a

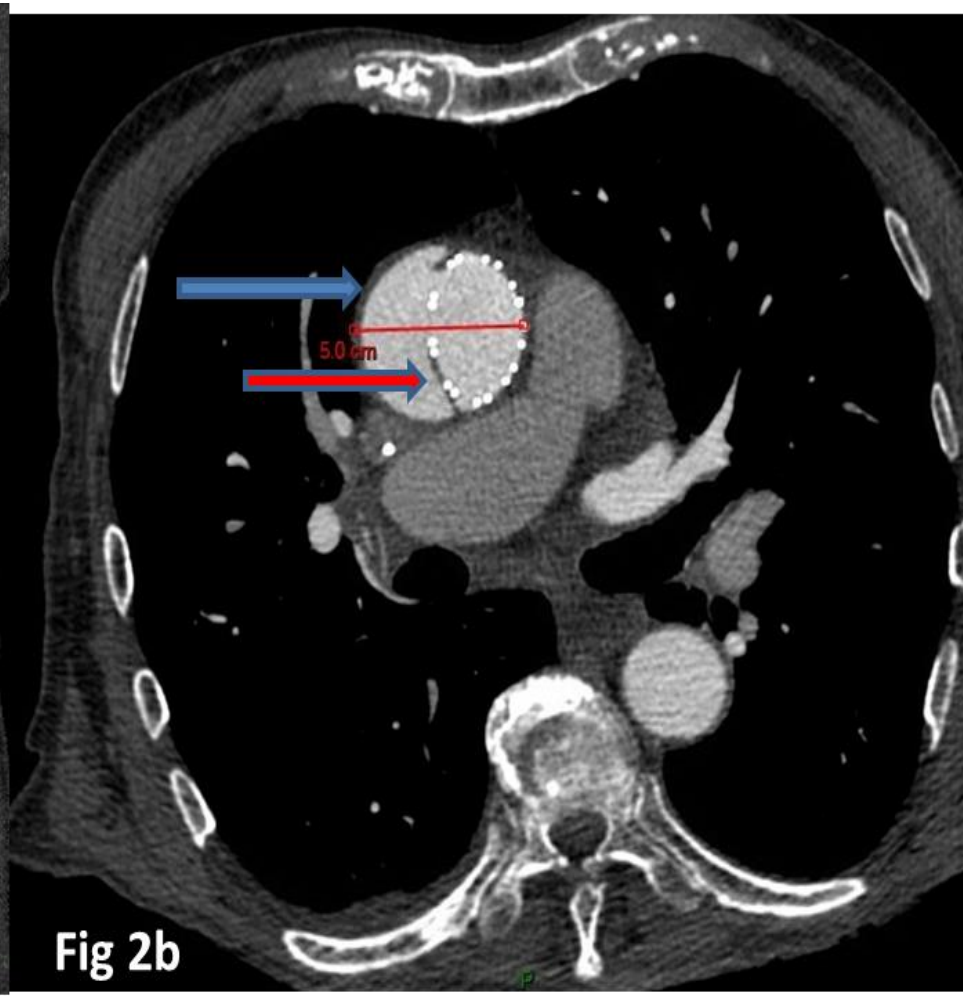

Fig 2b

Final Follow-up

In October 2017 he had pulmonary infection

A week of oral antibiotic at home he had pneumonia

Hospital for IV perfusion for pneumonia

Died for septic reasons at the age of 98 years

He did not had any Cardiac or Vascular Complication

CRITICAL DISSECTION : CASE 2

- Female, 74 ans
- Type A in 2008 , treated by Asc Ao Replacement and Hemiarch with an elephant trunk
- On follow-up for False Lumen dilatation

2010

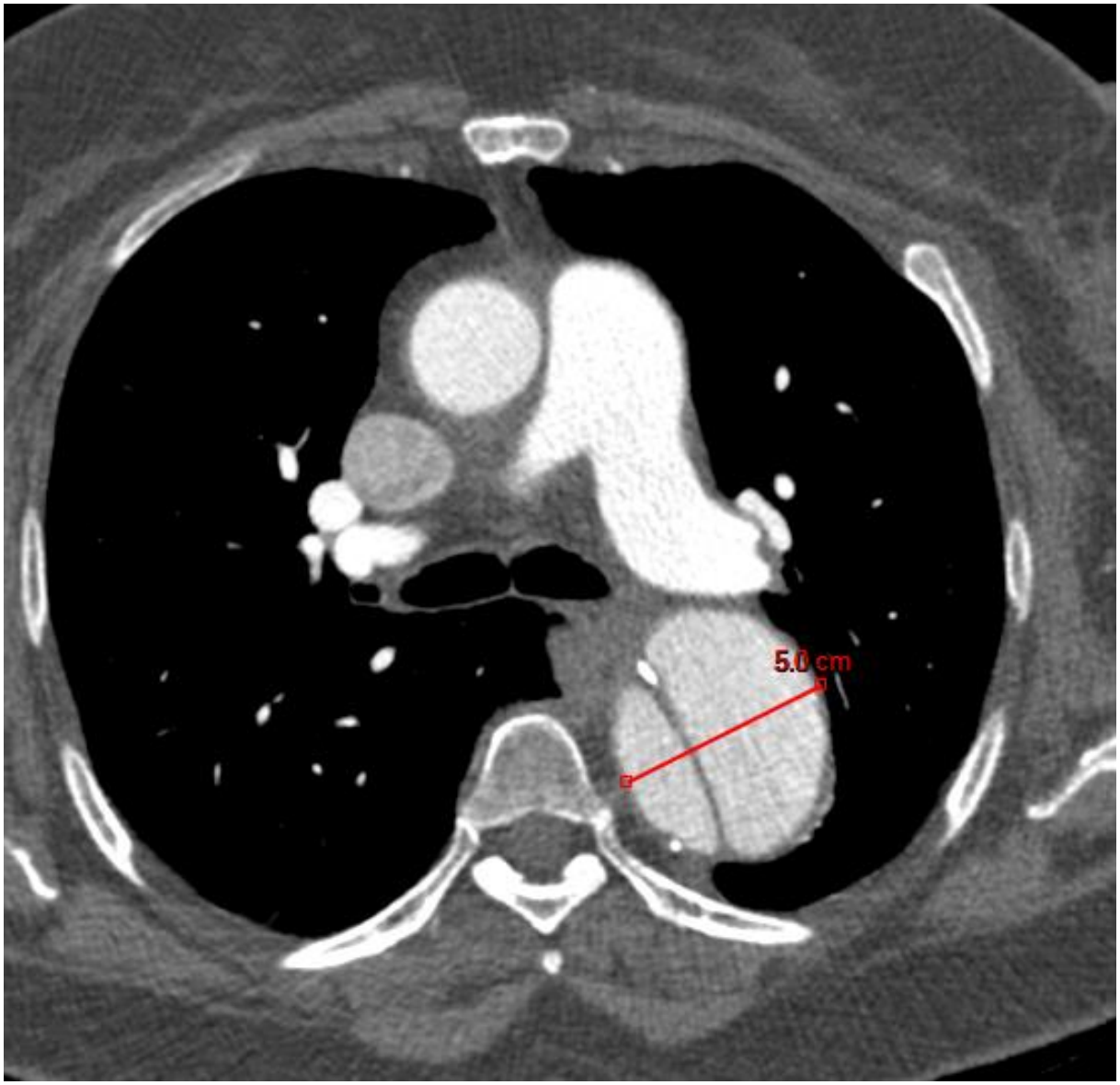

2017

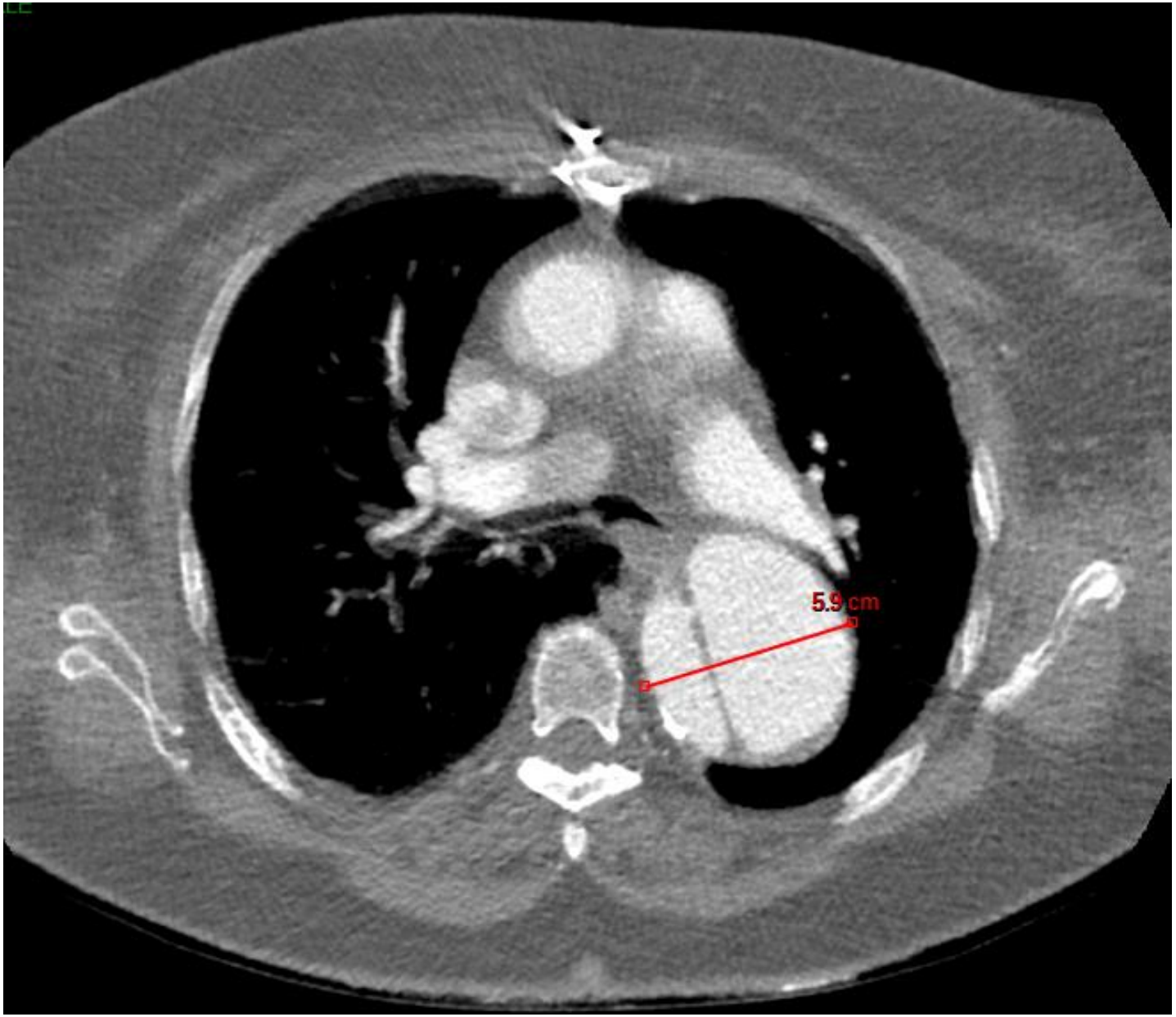

2017

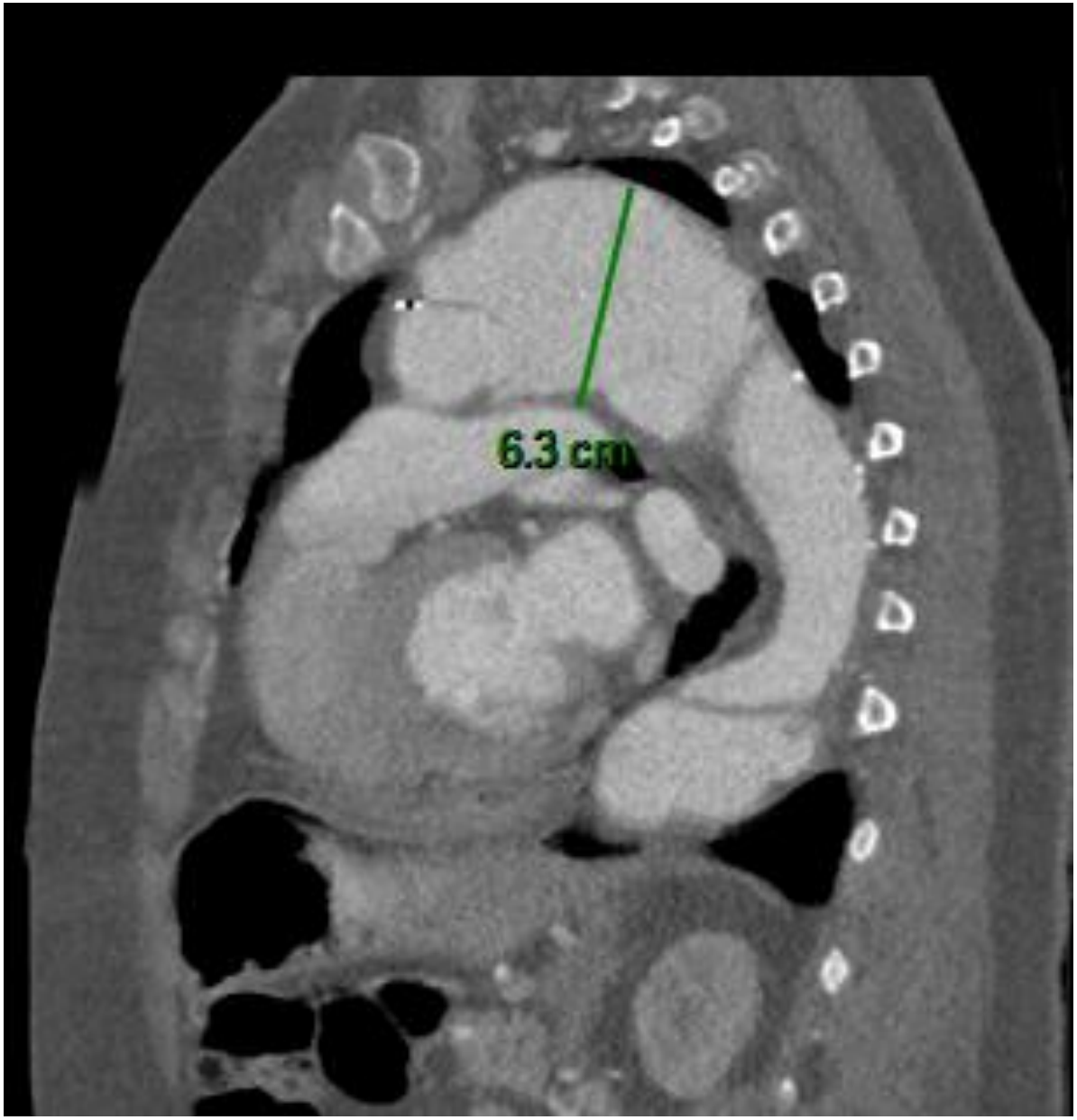

2017

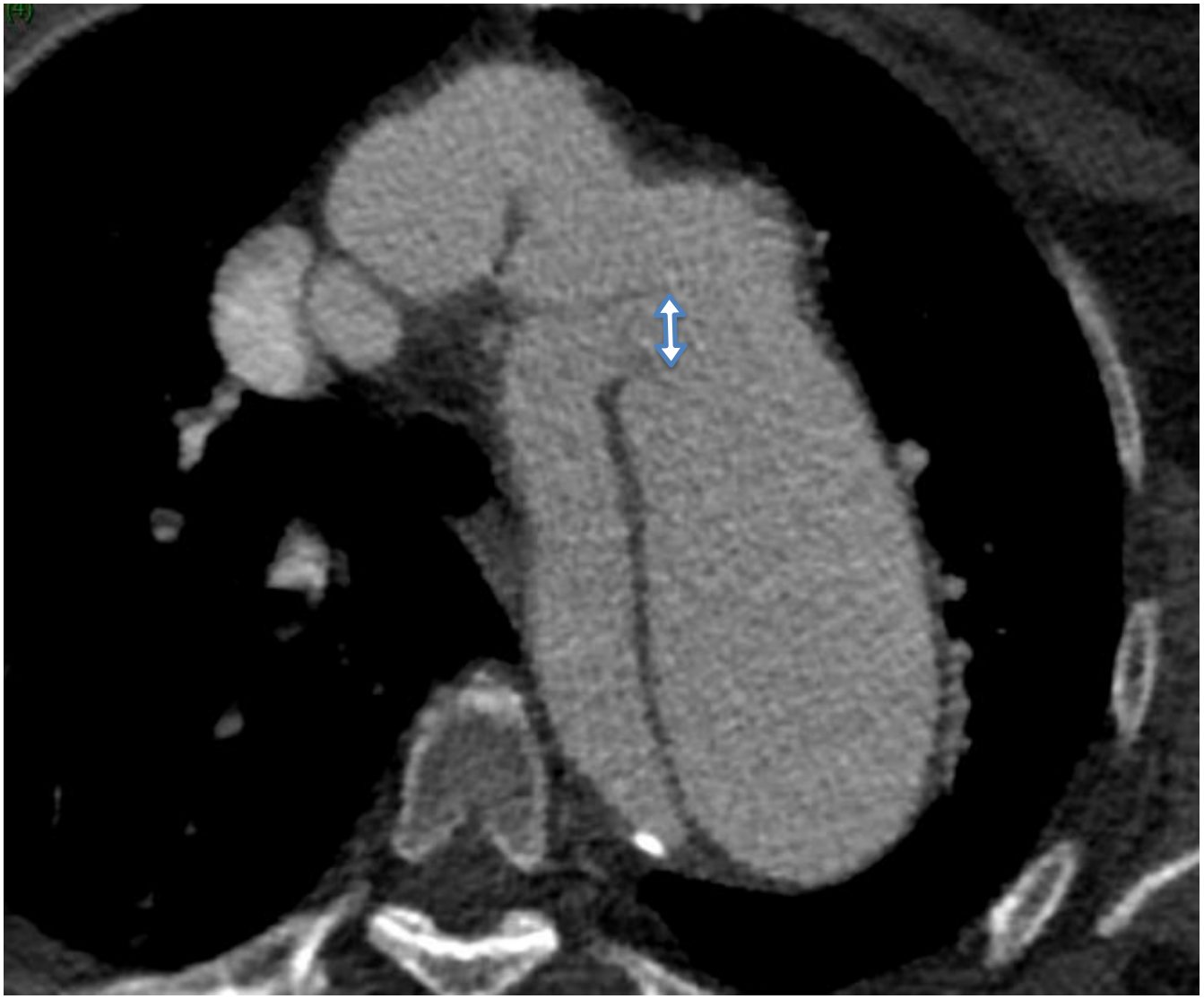

Catheter in FL

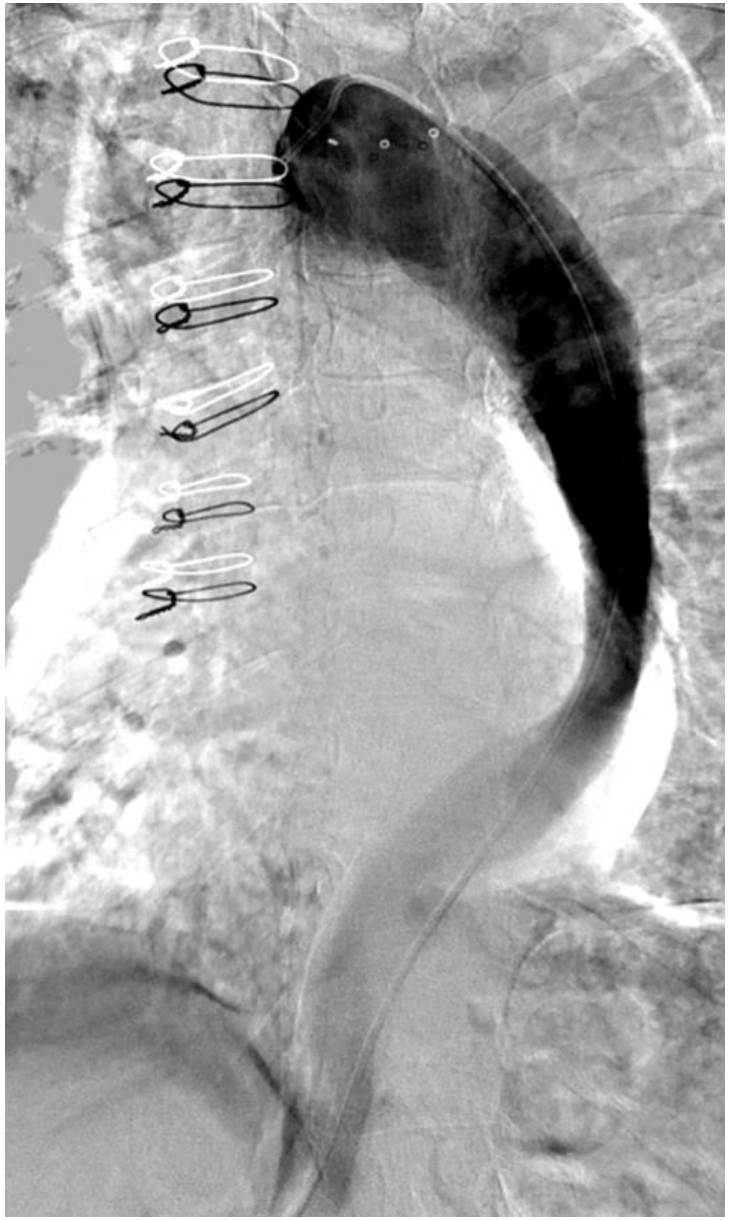

Catheter in FL again

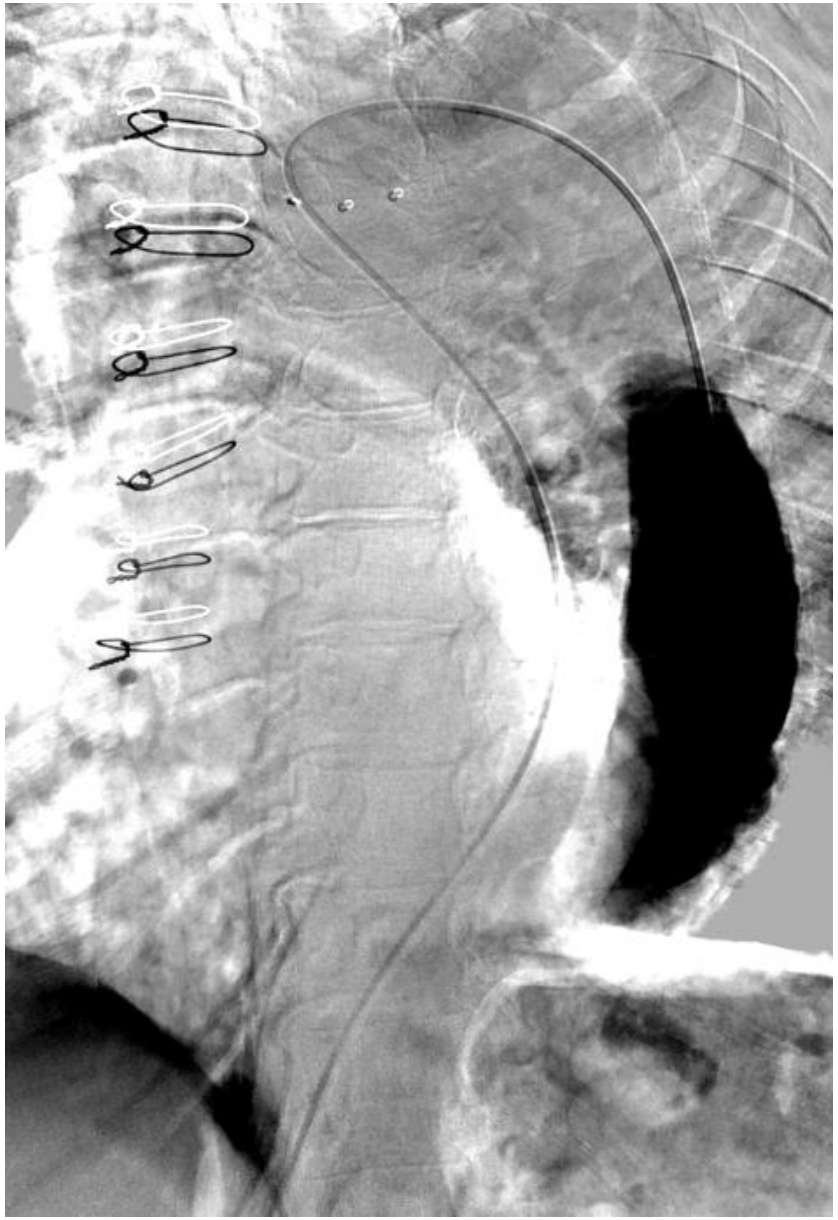

Injection from left arm

Catheter from the femoral

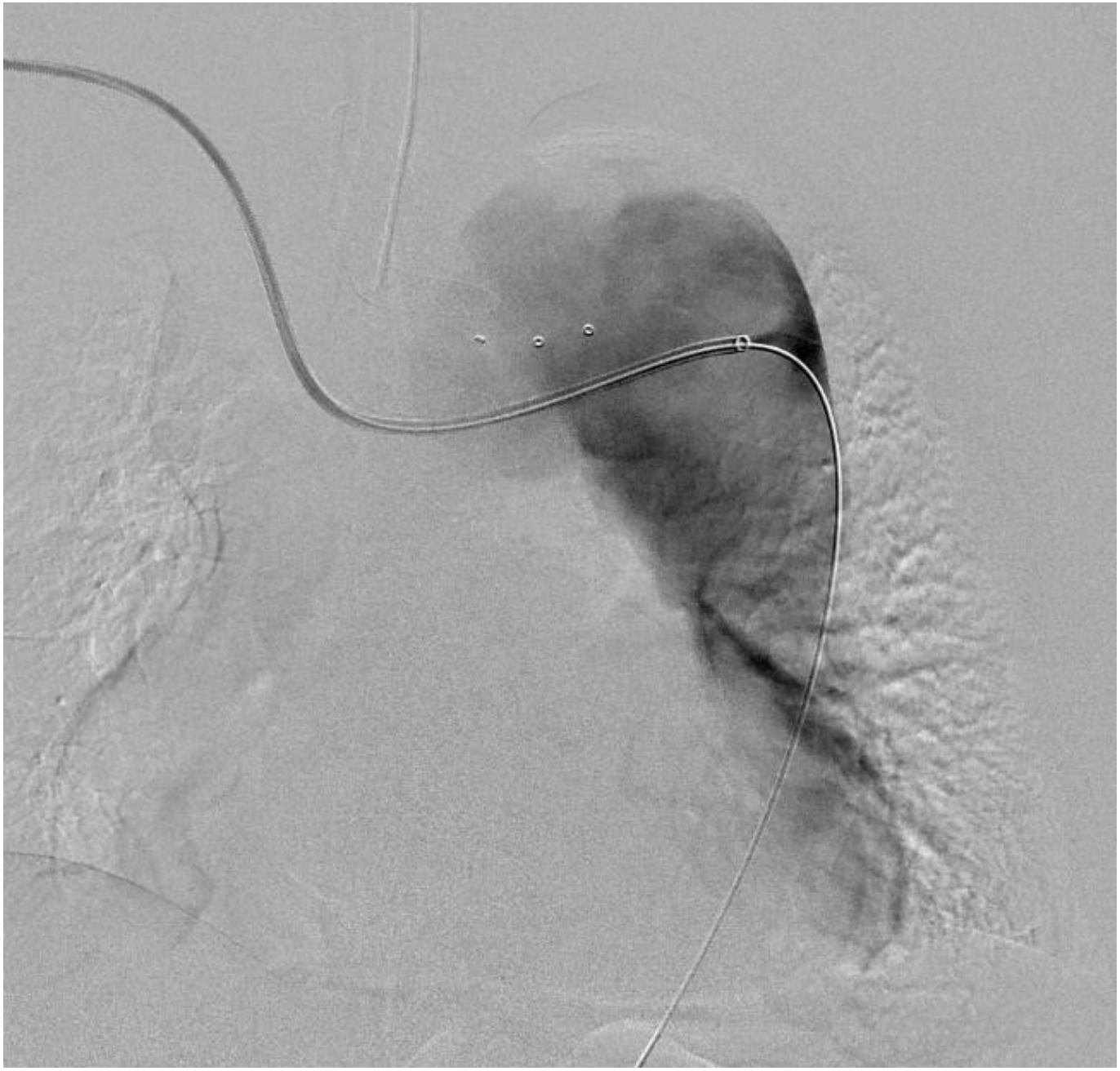

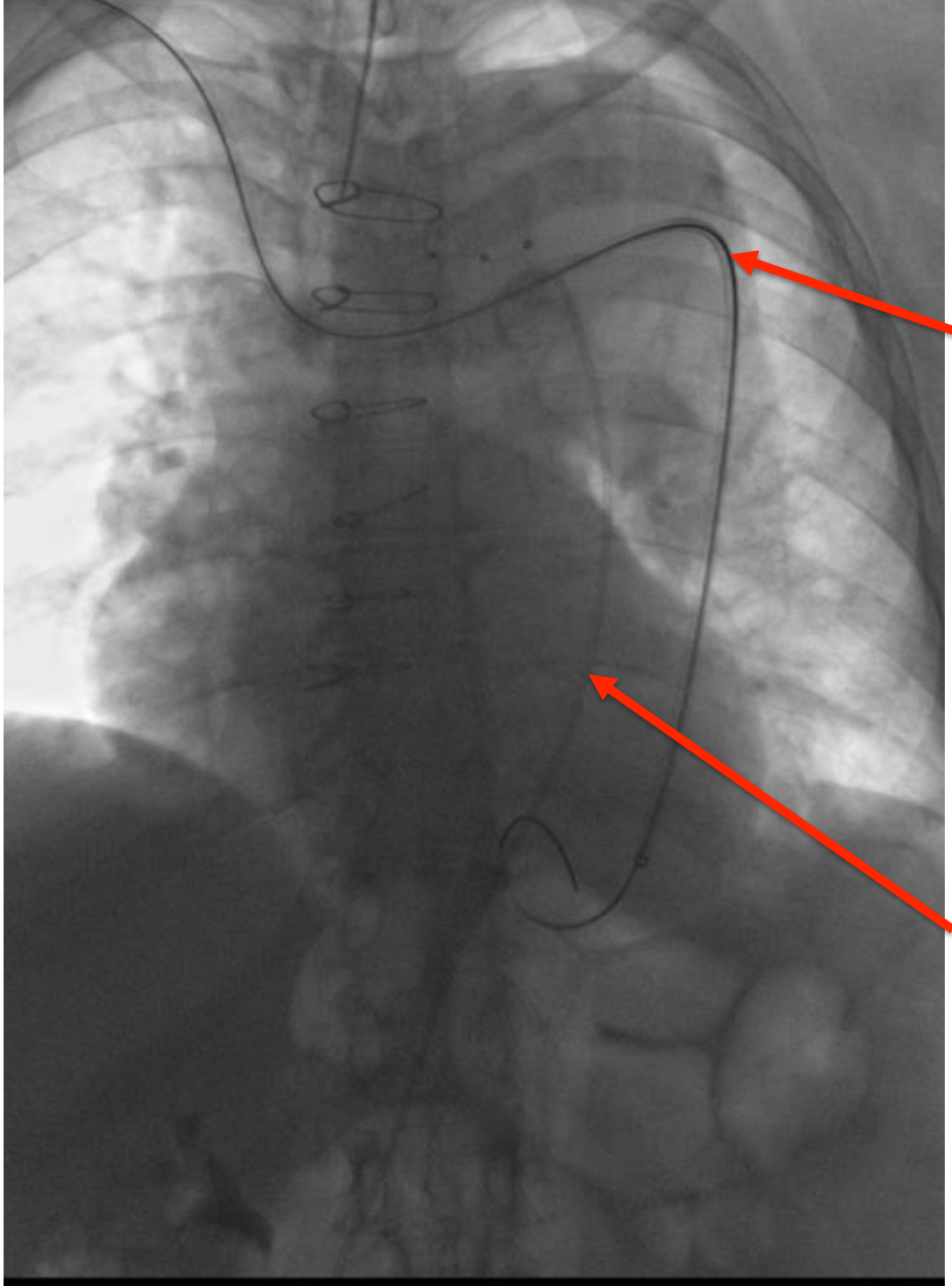
Right arm catheter in the FL
Femoral catheter in the TL

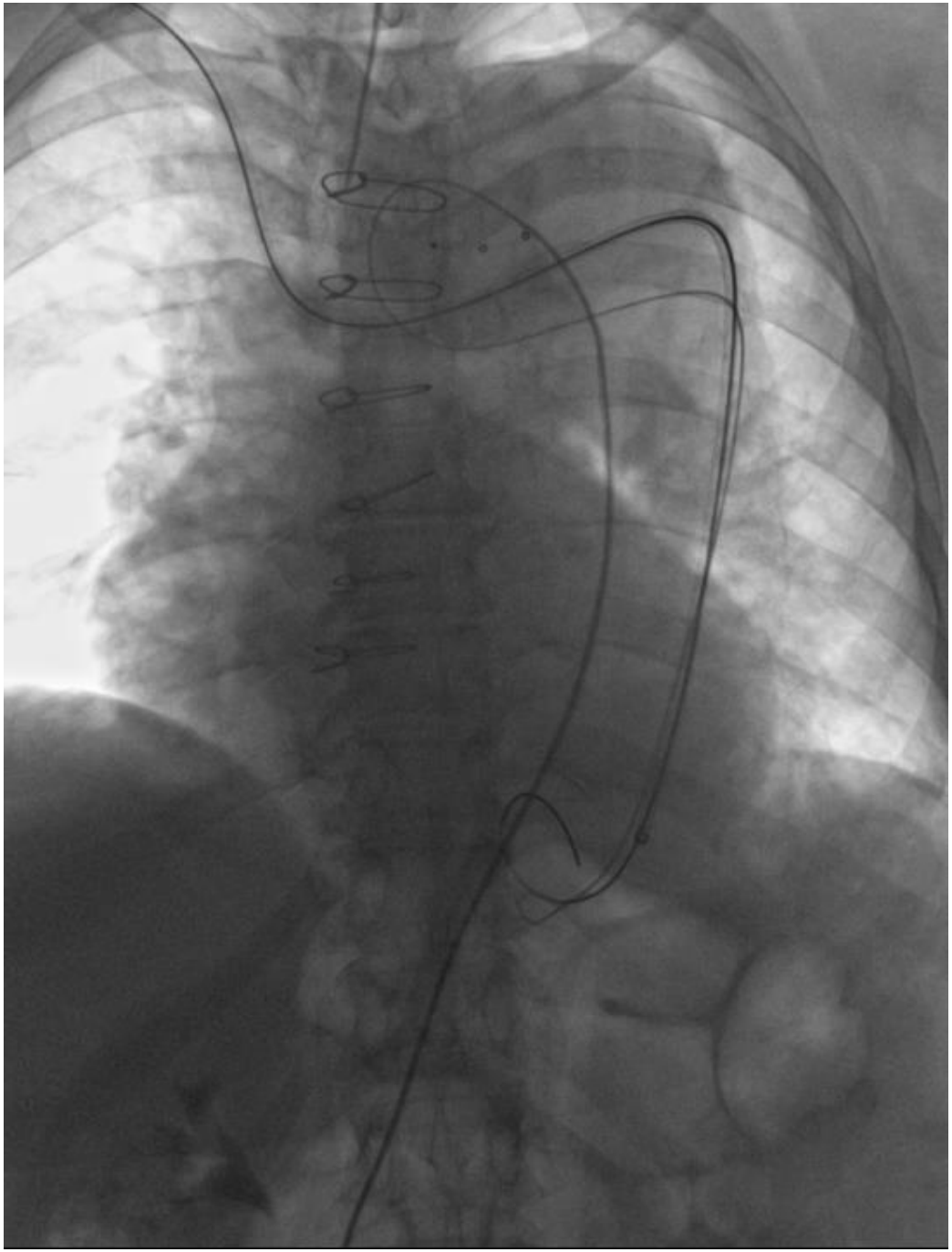

YES, we have a wire form femoral to right arm in TRUE Lumen

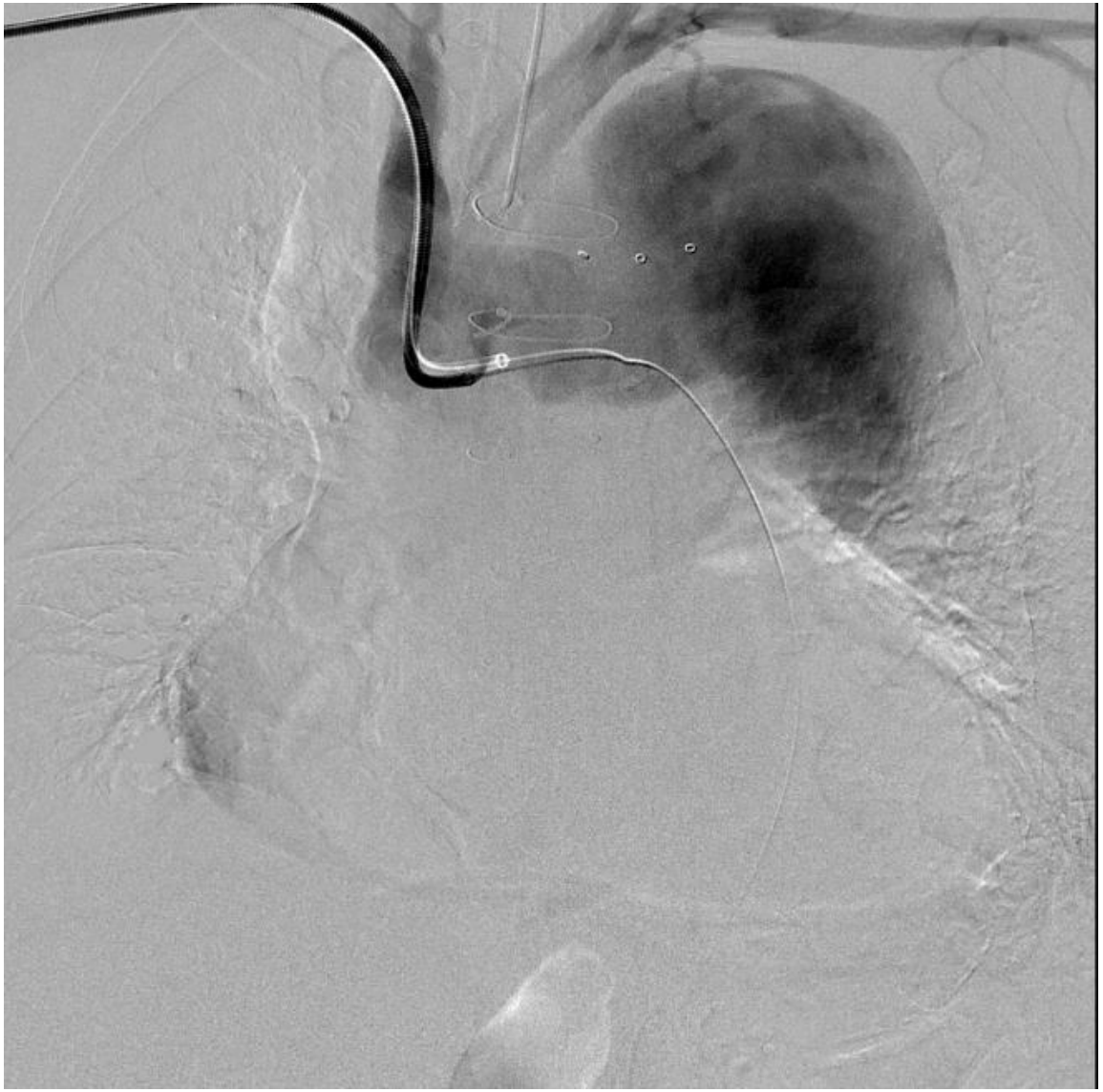

PTA of the flap between FL and FL

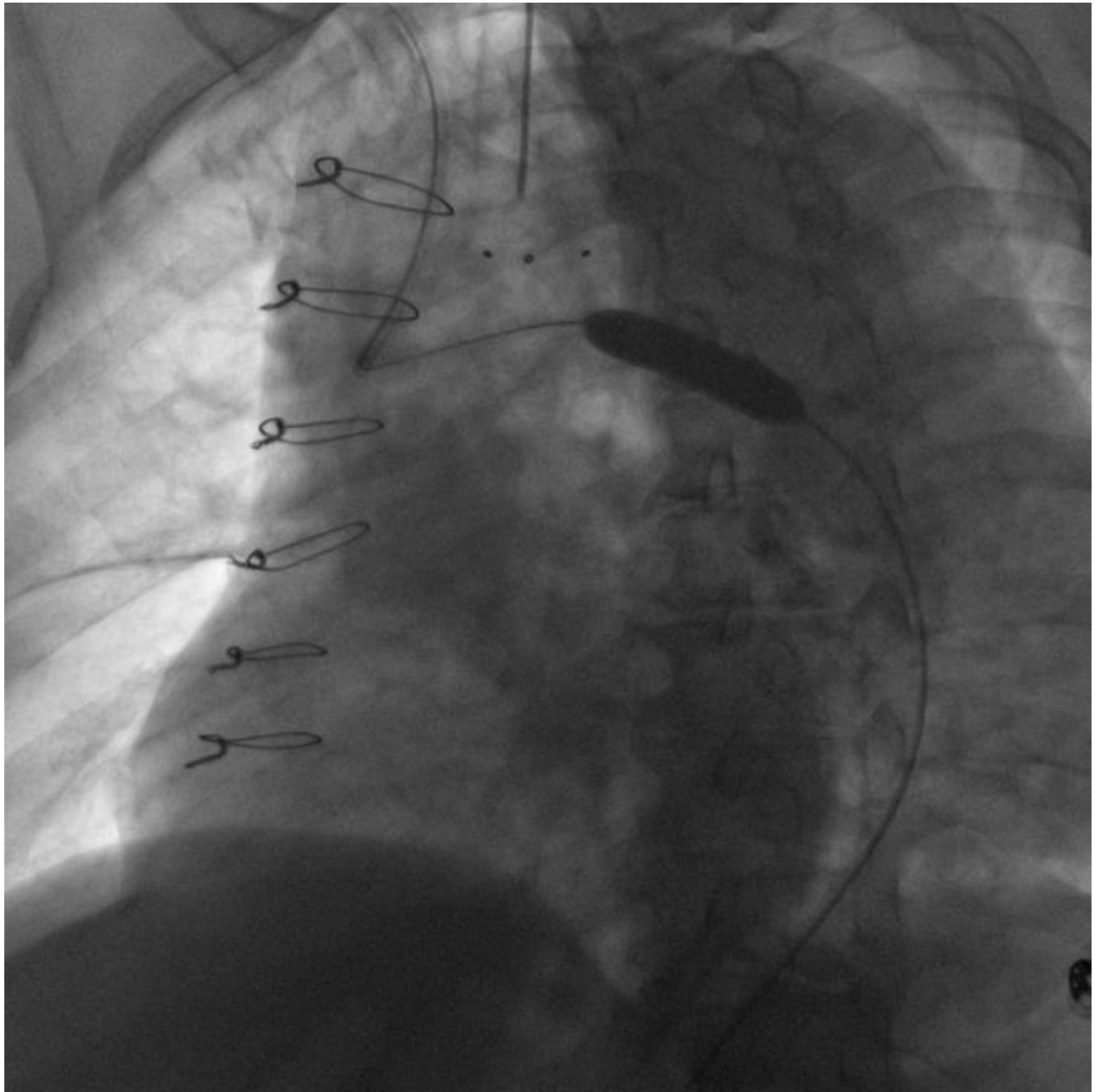

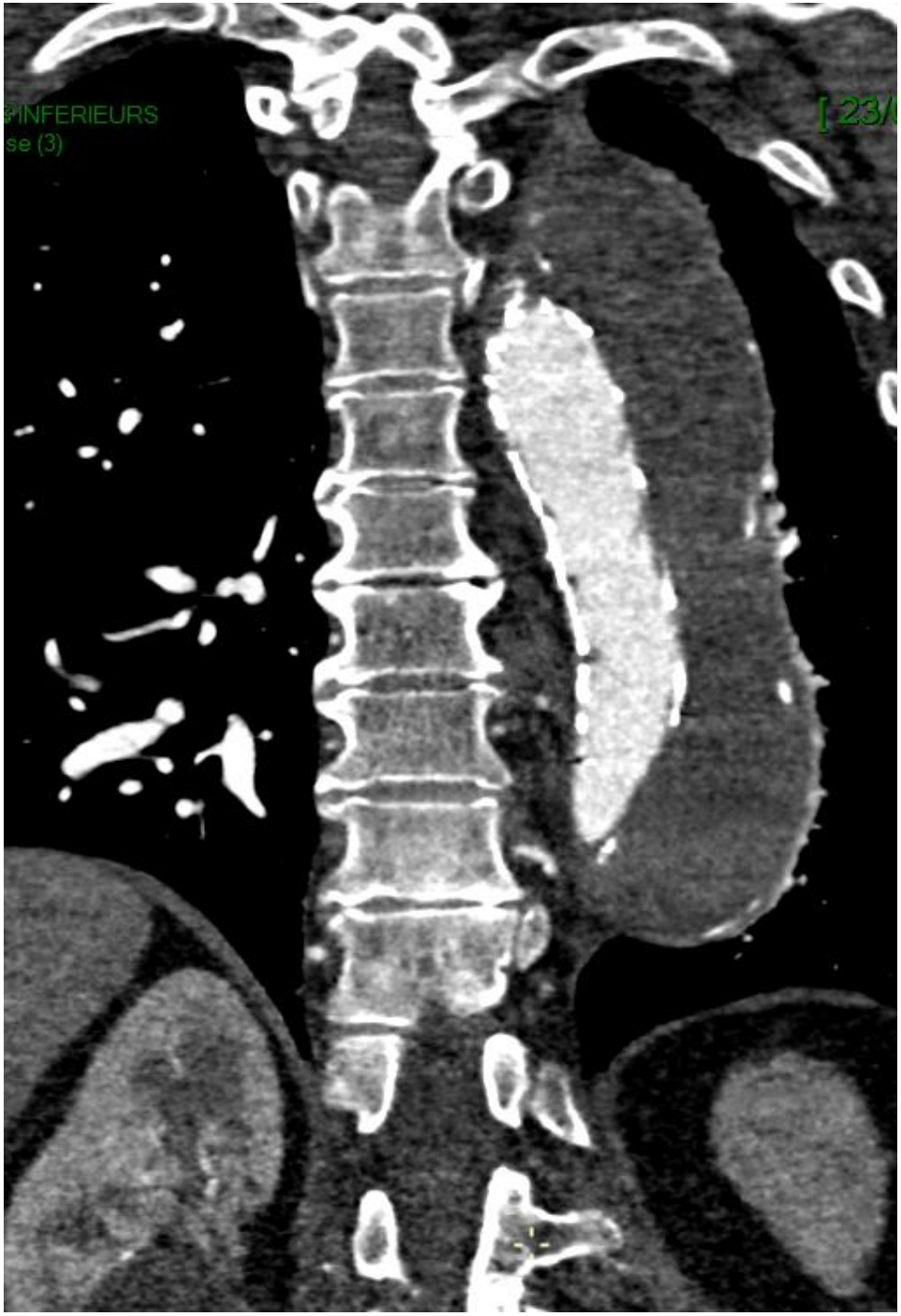
INFERIEURS
se (3)
[23/

Conclusion

1. When we surf at the edge of therapeutics and technologies we need to have a very **opened mind** and be able to deliver a **quick solution** for unusual complications by using **bailout strategies** that could save patients' lives.

Conclusion

1. When we surf at the edge of therapeutics and technologies we need to have a very **opened mind** and be able to deliver a **quick solution** for unusual complications by using **bailout strategies** that could save patients' lives.
2. Material knowledge and guide wire skills are the key of success.

Conclusion

1. When we surf at the edge of therapeutics and technologies we need to have a very **opened mind** and be able to deliver a **quick solution** for unusual complications by using **bailout strategies** that could save patients' lives.
2. Material knowledge and guide wire skills are the key of success.
3. Minimal invasive approach for complex disease is a good alternative.

Conclusion

1. When we surf at the edge of therapeutics and technologies we need to have a very **opened mind** and be able to deliver a **quick solution** for unusual complications by using **bailout strategies** that could save patients' lives.
2. Material knowledge and guide wire skills are the key of success.
3. Minimal invasive approach for complex disease is a good alternative.
4. Minimal invasive follows the natural evolution of the society.