

Male 78 years old with diffuse severe centrilobular emphysema

Presented with hypotension 80mmHg  
He had a CT and went to the OR

## **CT findings**

**7.8x 7.2 cm** infra-renal AAA

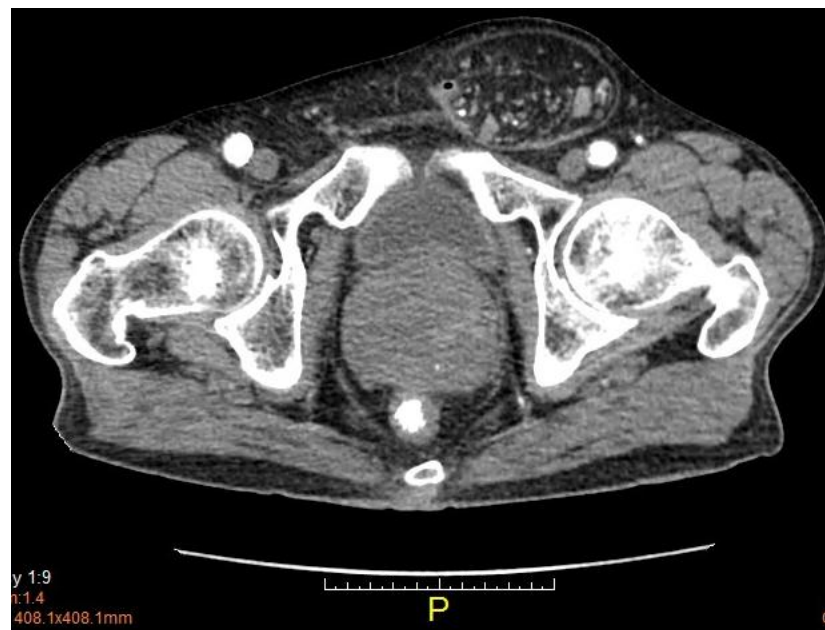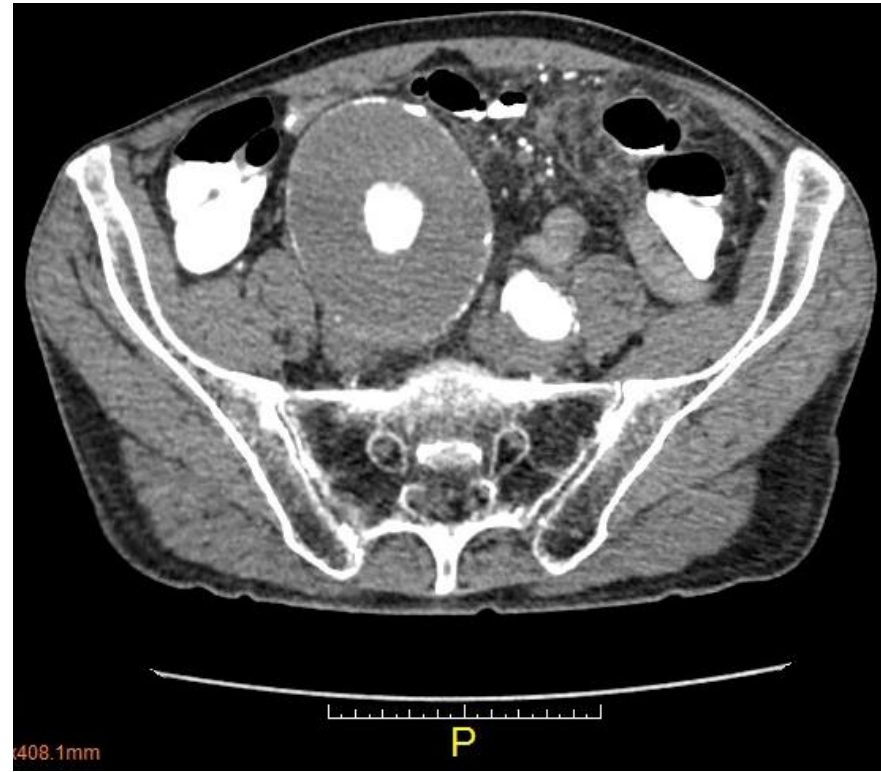
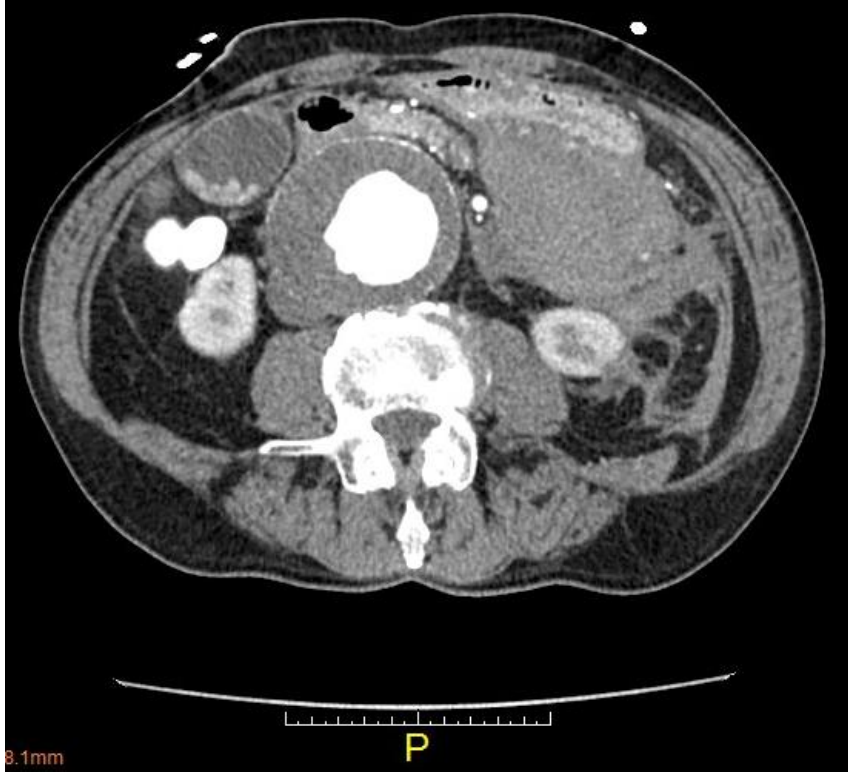
No evidence of active extravasation

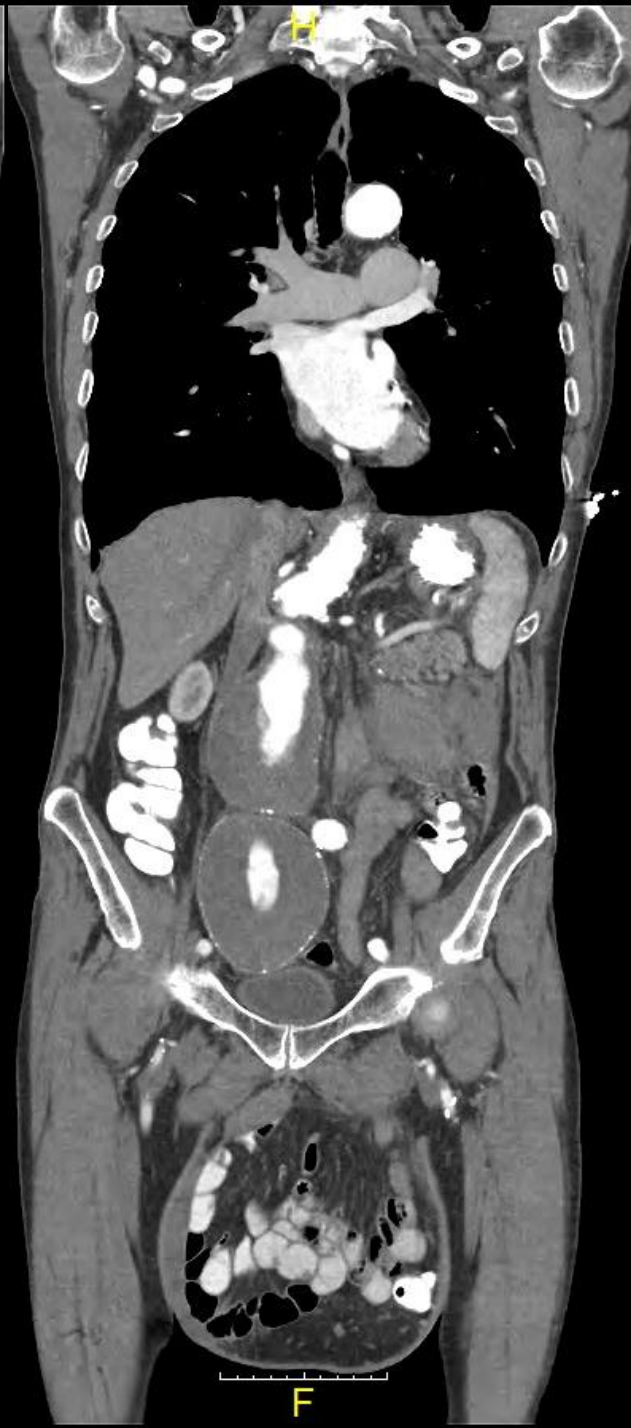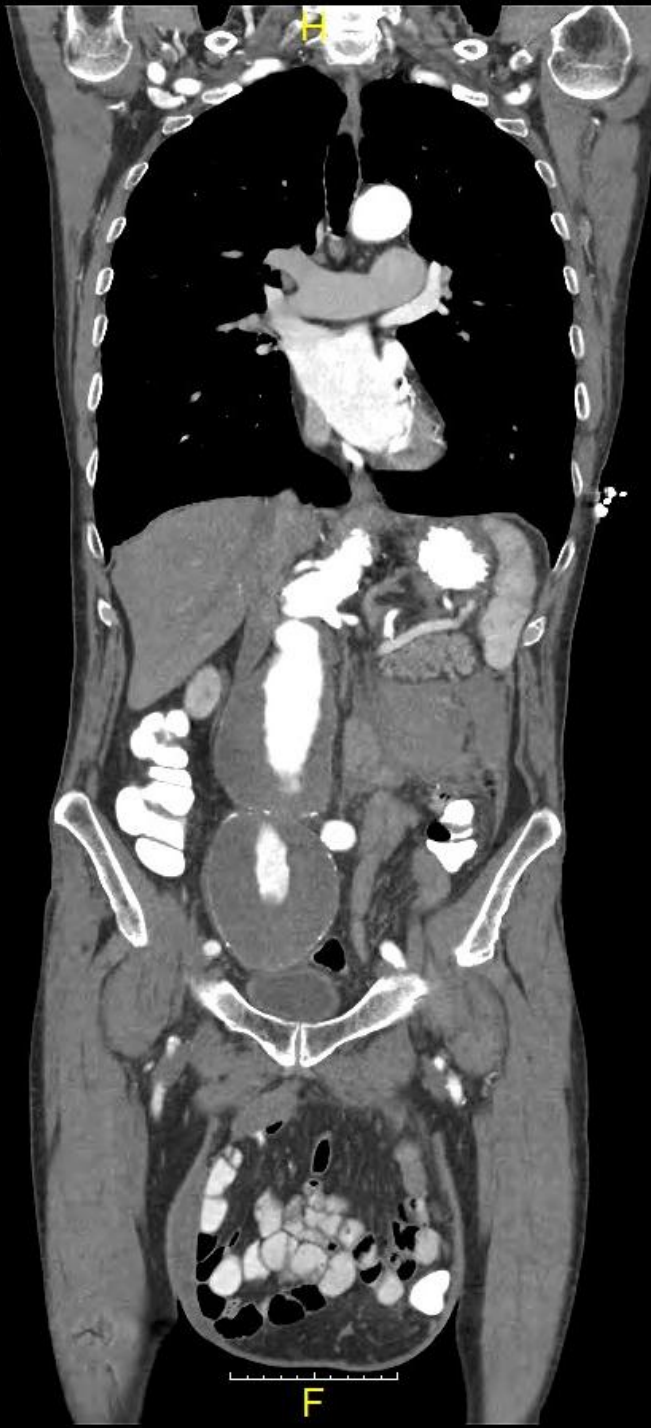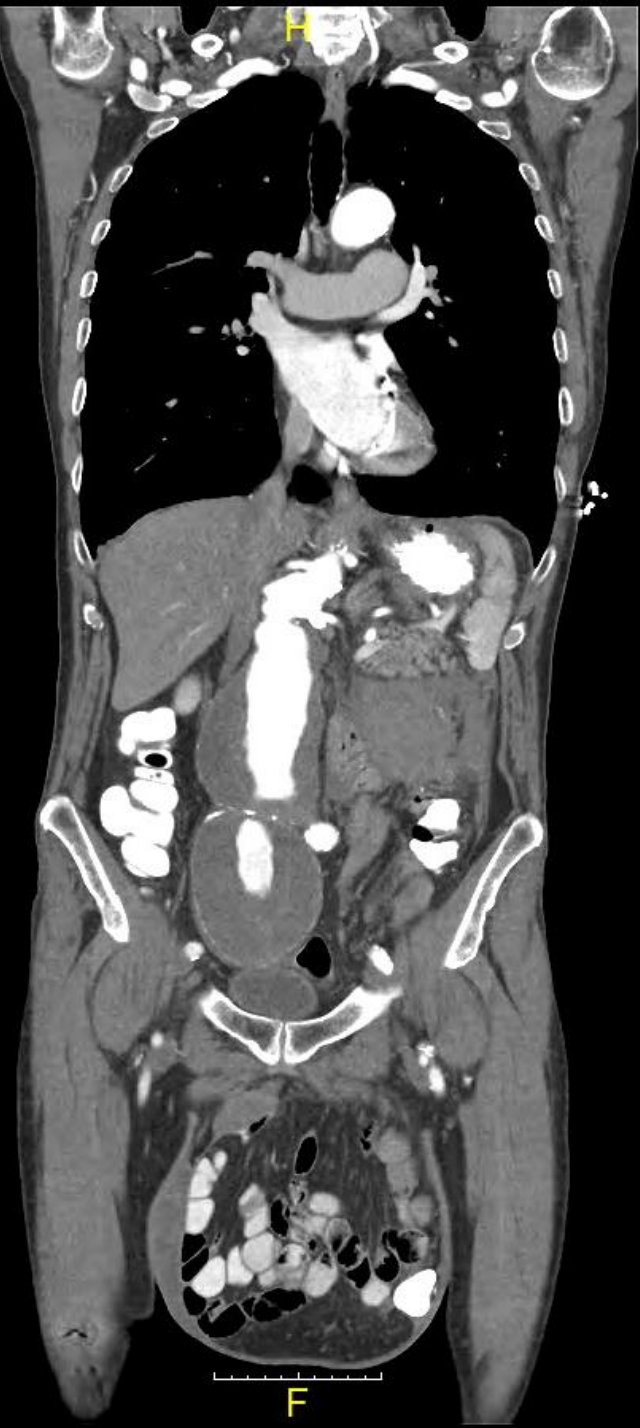**RT CIA 7.9 cm**

**LT CIA 3.1cm**

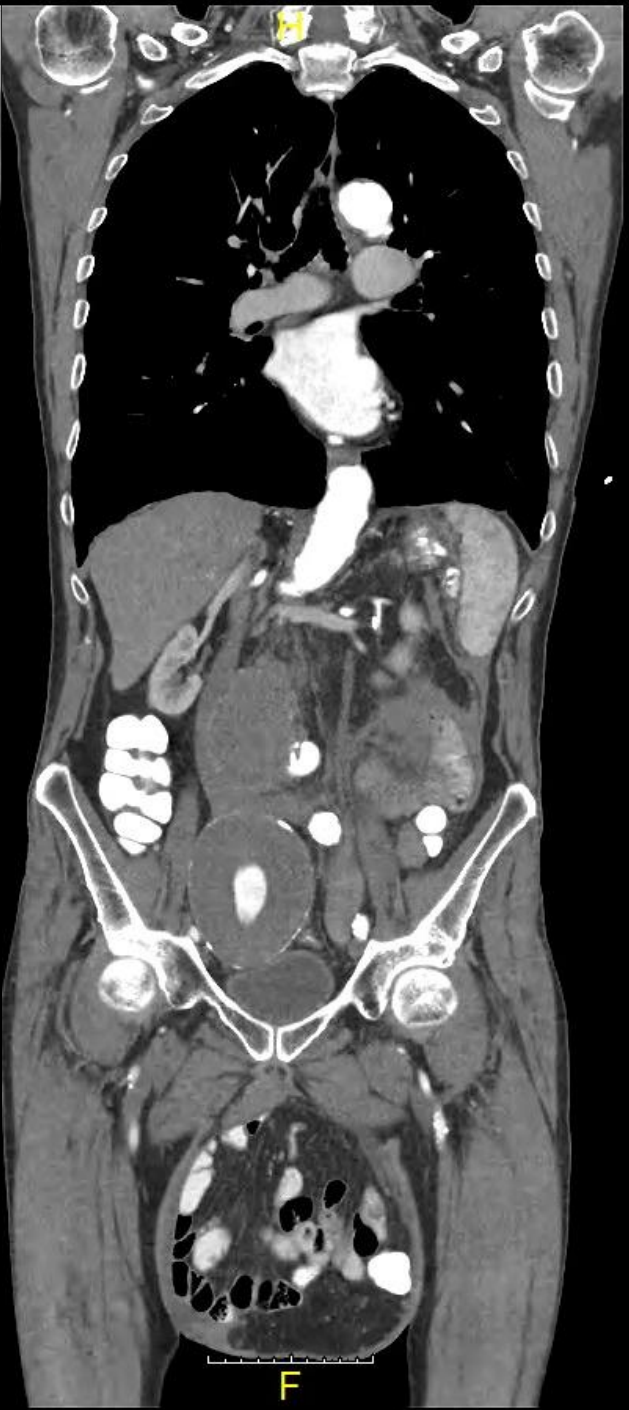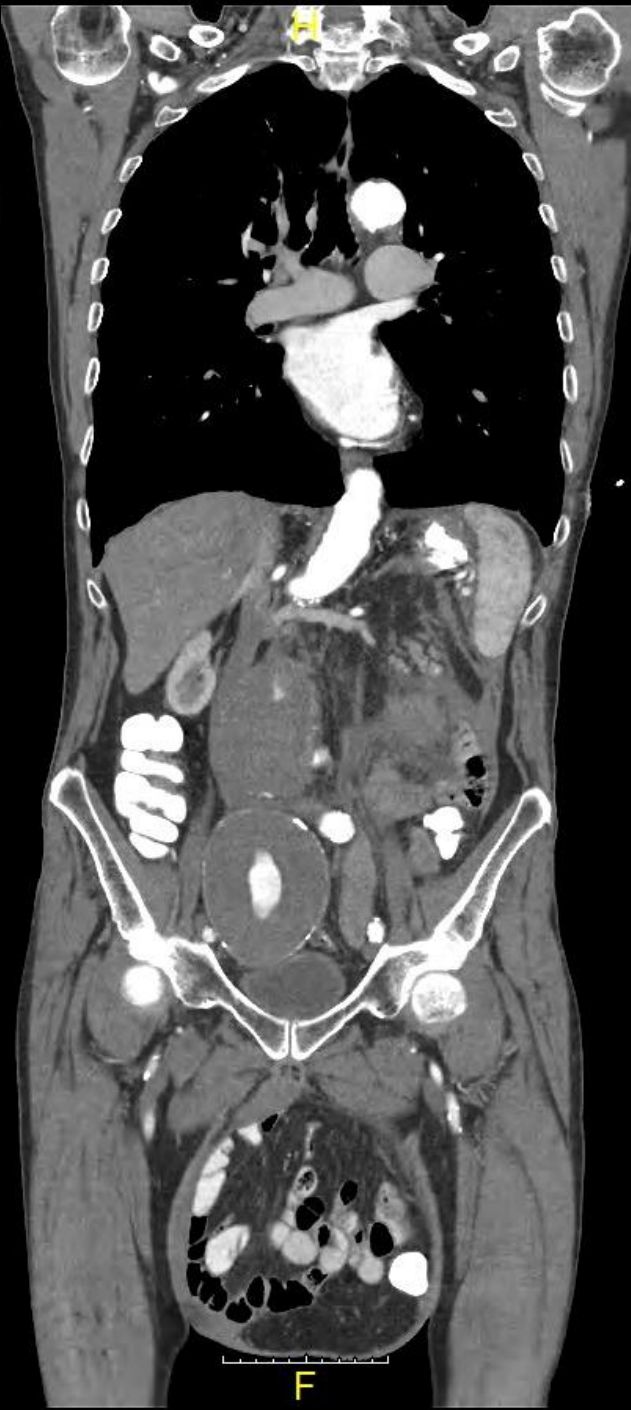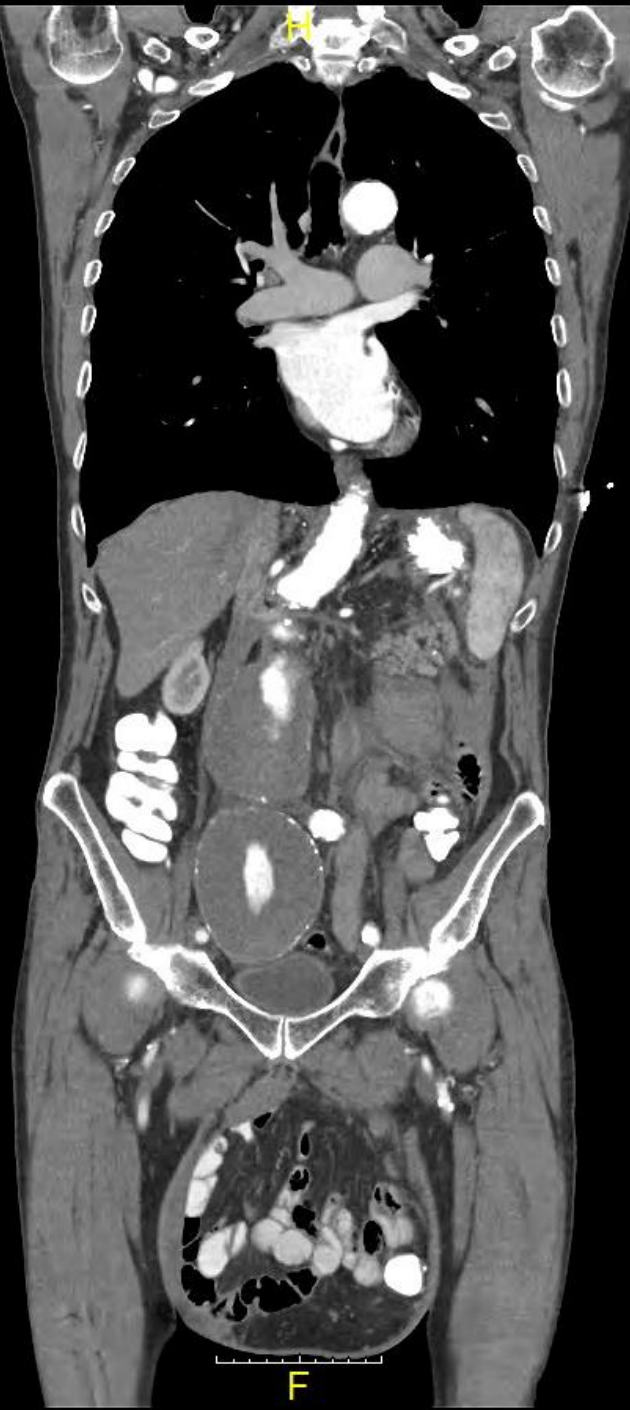Both internal iliac arteries are patent

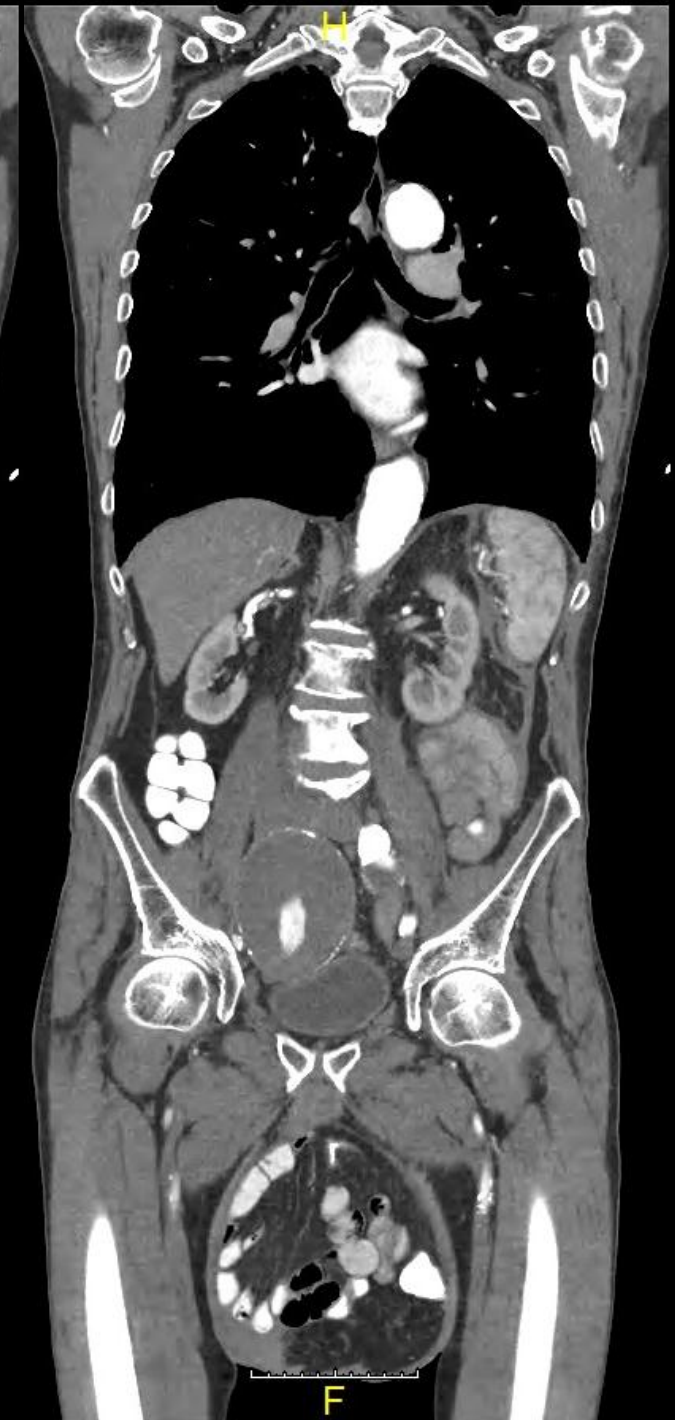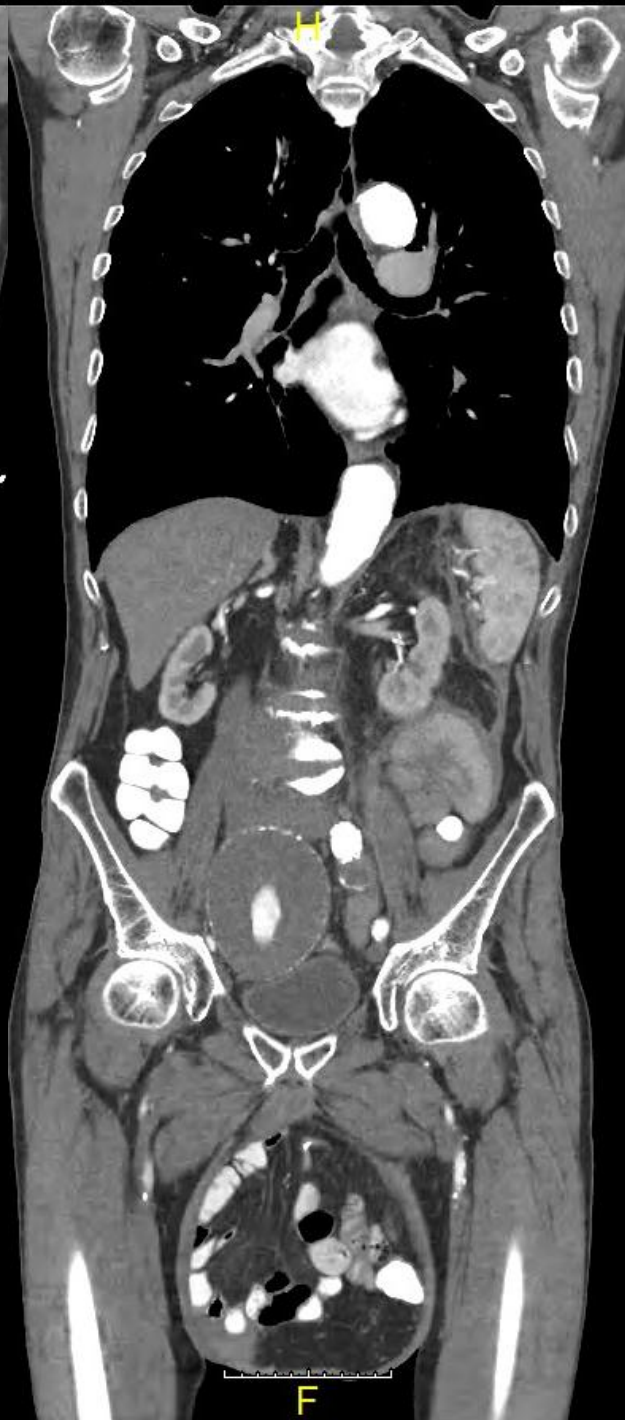
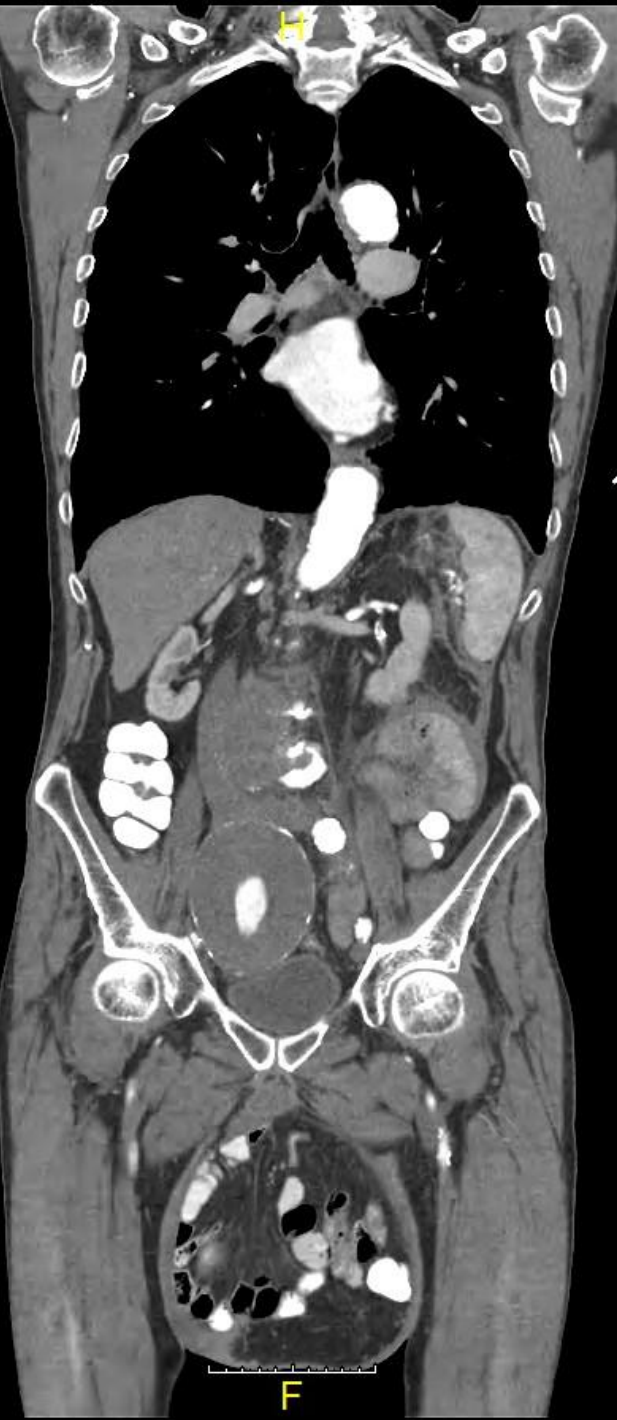Large hemorrhage deep to the stomach and greater omentum and superficial to jejunal mesentery, large IP hemorrhage layering within a humongous left inguinal canal hernia containing the majority of the small bowel.



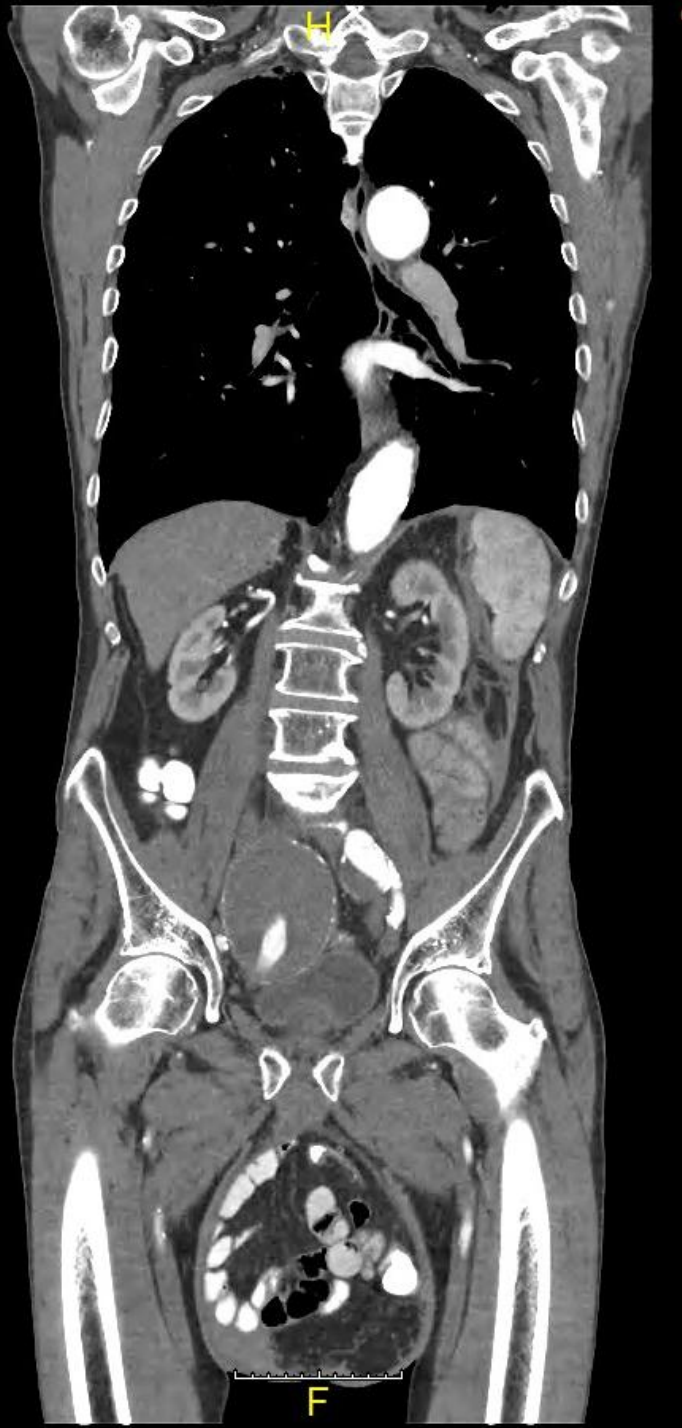
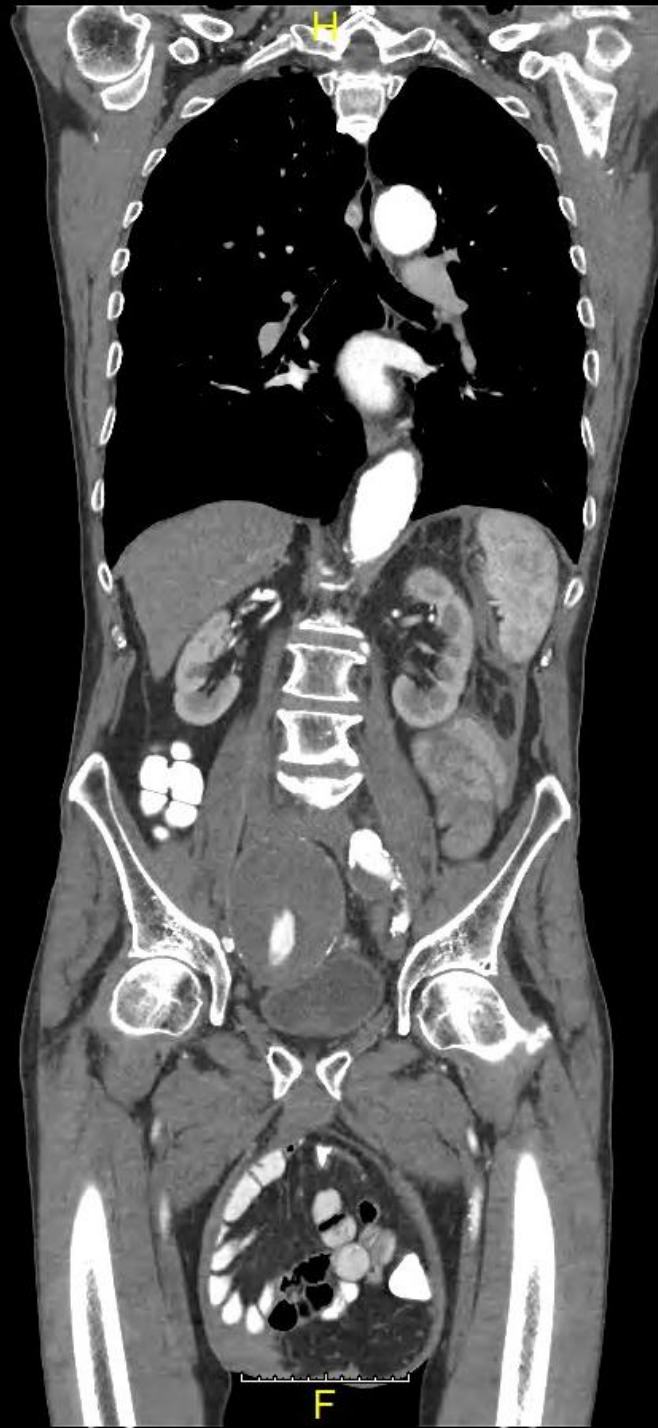


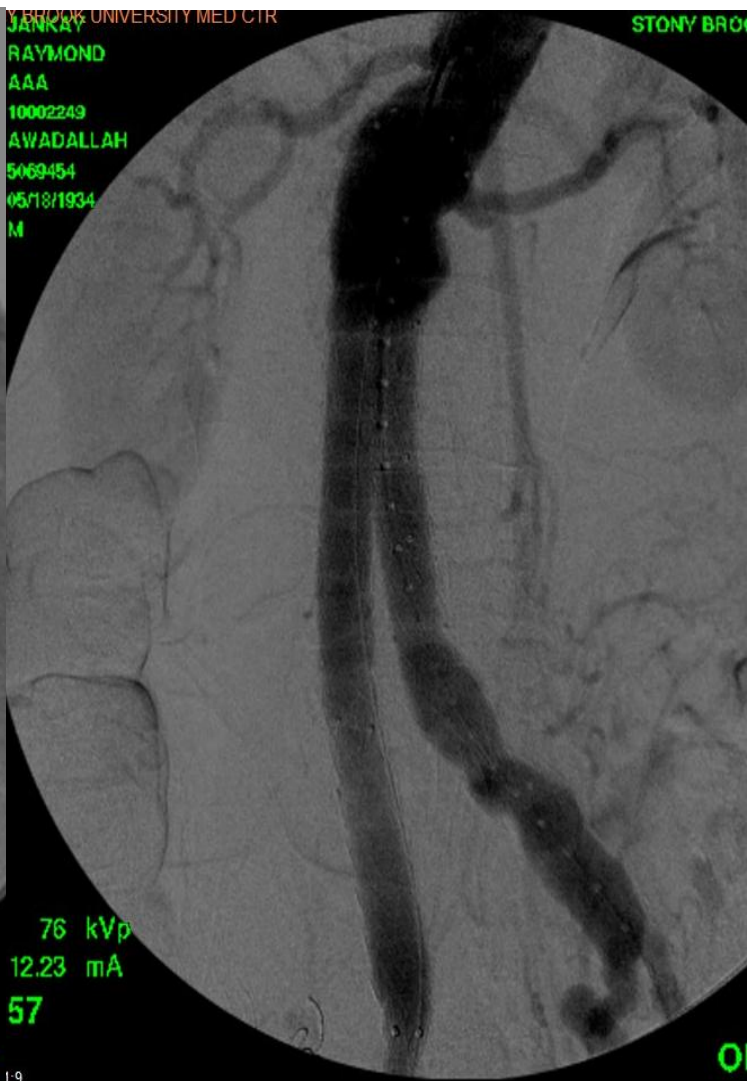
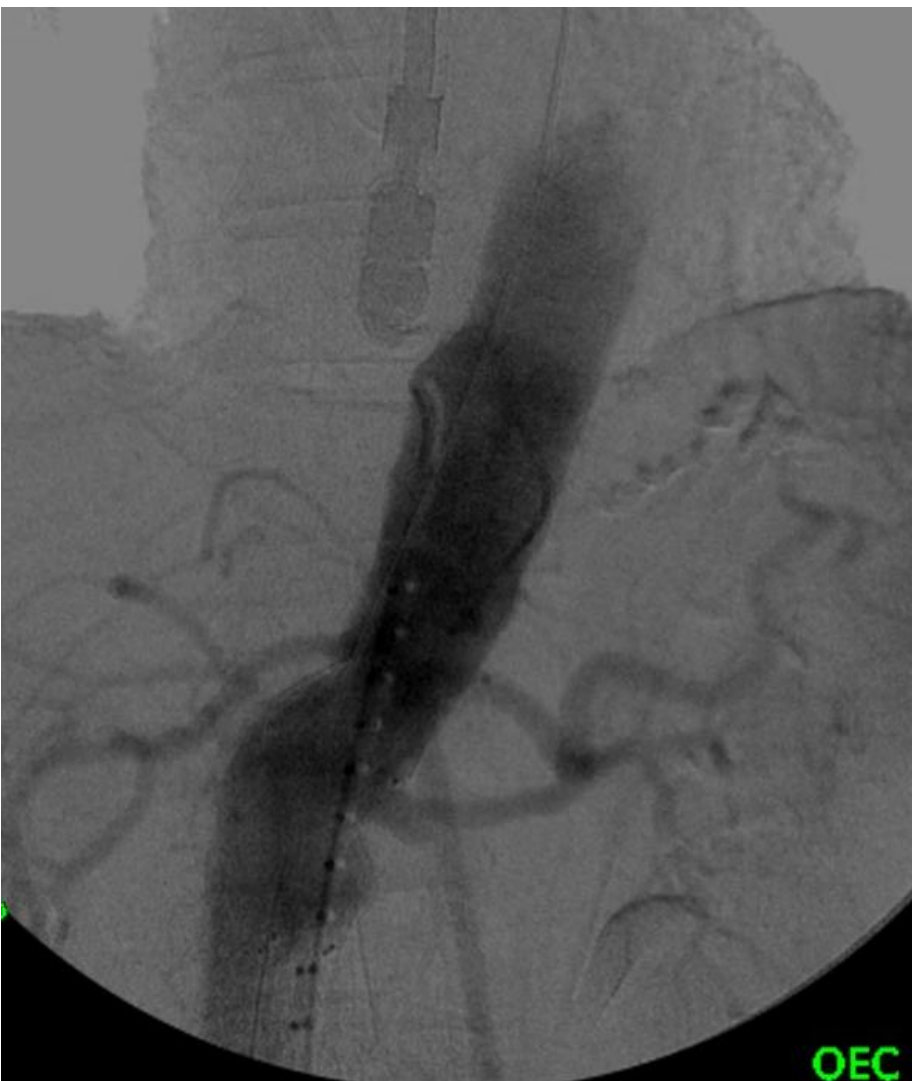








Y BROOK UNIVERSITY MED CTR

STONY BROOK

JANKAY  
RAYMOND  
AAA  
10002249  
AWADALLAH  
5069454  
05/18/1934  
M

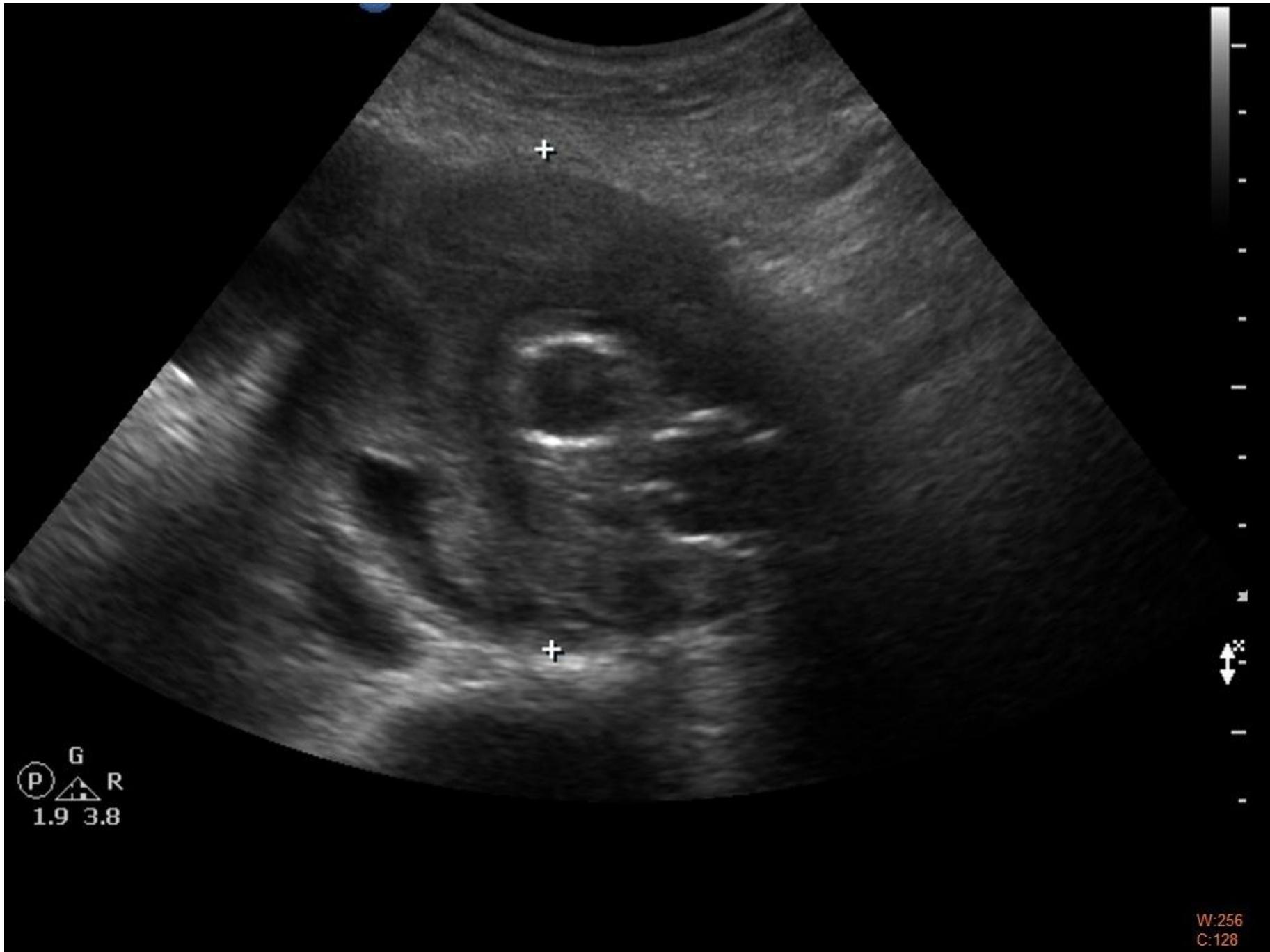
76 kVp  
12.23 mA  
57

OEC

1:9

O





**Posto-op**

**Developed MI needing a CABG x4**

**Withdrew care and died on day 10**

# Debate and interactive discussion

## Clinical case debate: for/against

**EVAR or not EVAR for ruptured AAA?**

**EVAR and more EVAR for ruptured AAA?**




**IMAD 2012** IS PROUD TO PRESENT TO YOU

**A special transatlantic live event!**

**FRANK VS. FRANK!!**

**FRANK with FRANK!!**

# 20<sup>th</sup> anniversary of the first EVAR in USA



**Is a randomized trial necessary to determine whether endovascular repair is the preferred management strategy in patients with ruptured abdominal aortic aneurysms?**

**Veith FJ, Powell JT, Hinchliffe RJ. J Vasc Surg 2010;52:1087-93**

# Endovascular repair of aortic rupture.

Van Herzeele I, **Vermassen F**, Durieux C, Randon C, De Roose J.  
Eur J Vasc Endovasc Surg 2003;26:311-6





# **The status of EVAR for ruptured AAAs**

## **Frank Veith**



# **EVAR for ruptured AAAs early results**

## **Frank Vermassen**