WHAT IS THE BEST OPTION FOR ARCH ANEURYSMS?

Prof. Furuzan Numan M.D
Chief of Interventional Radiology Department
Cerrahpasa Medical Faculty & Memorial Hospital,
ISTANBUL, TURKIYE
3ad INTERNATIONAL MEETING ON AORTIC ARCH
2012 LIEGE

Disclosure Medtronic

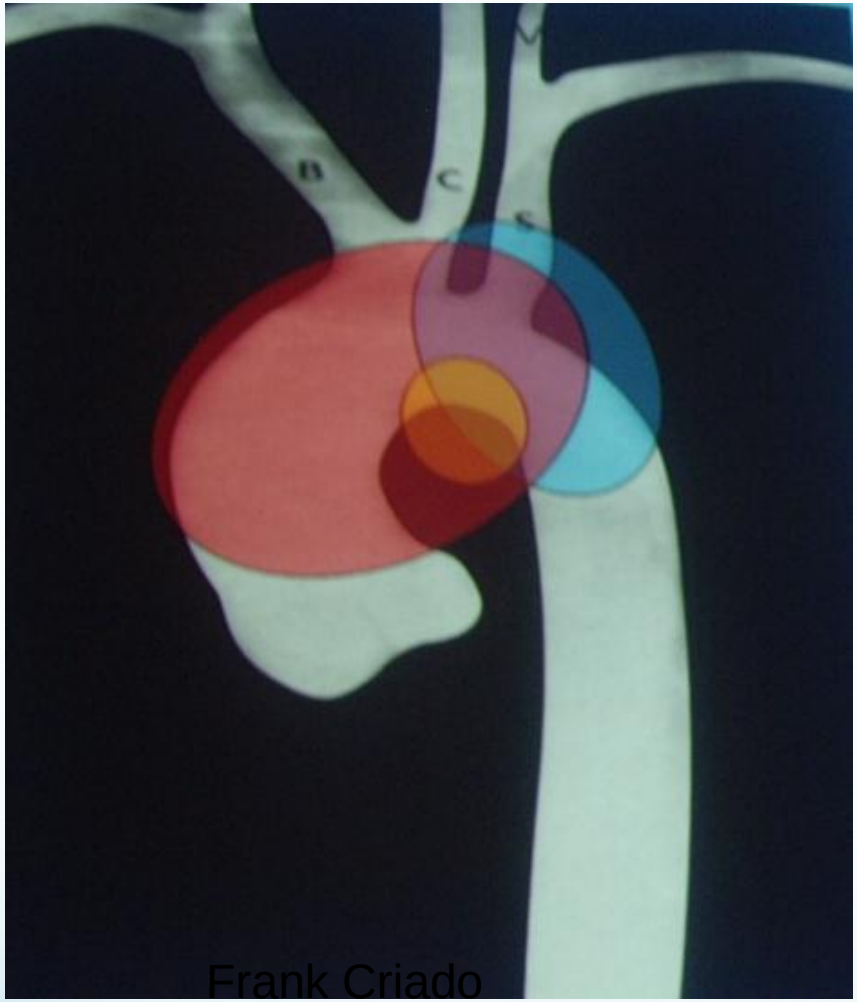

- Penetrating Ulcers
- Aneurysms
- Retrograde typeB Dissection
- Transsection

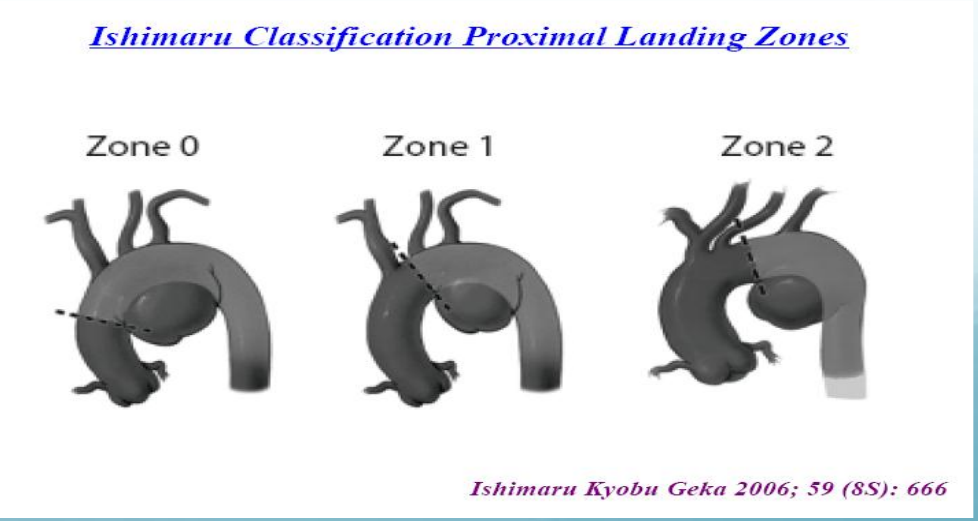

HYBRID

J Cardiovasc Surg (Torino). 2010 Dec;51(6):807-19.

Hybrid procedures for the treatment of aortic arch aneurysms.

Eagleton MJ, Greenberg RK.

Abstract

Historically, open repair has been the mainstay of therapy, but it is associated with significant morbidity and mortality.

Partial arch reconstruction may provide a viable alternative to conventional aortic arch surgery.

The further evolution of aortic endograft technology, however, will ultimately allow for complete endovascular treatment of the entire aortic arch.

RECENT ENDOVASCULAR OPTIONS TO REPAIR AORTIC ARCH

Modular Branched

Double Barrell

Chimney

Branched

Hemi Aortic Arch Reconstruction by In-Situ Fenestration Technique LSA/LCCA

Total Aortic Arch Reconstruction by In-Situ Fenestration technique

MODULAR BRANCHED

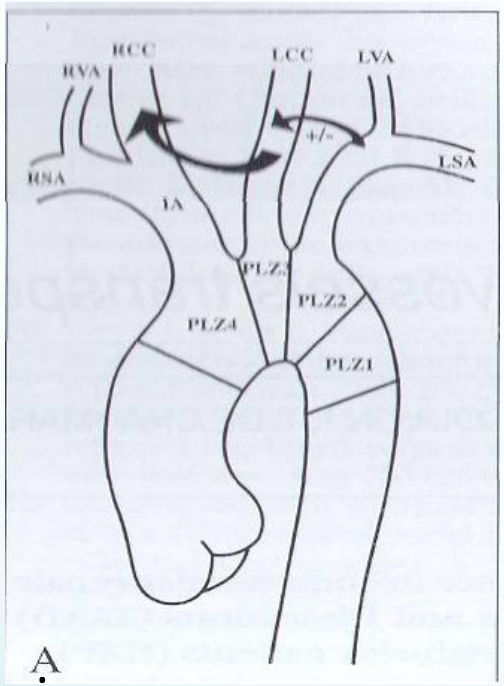

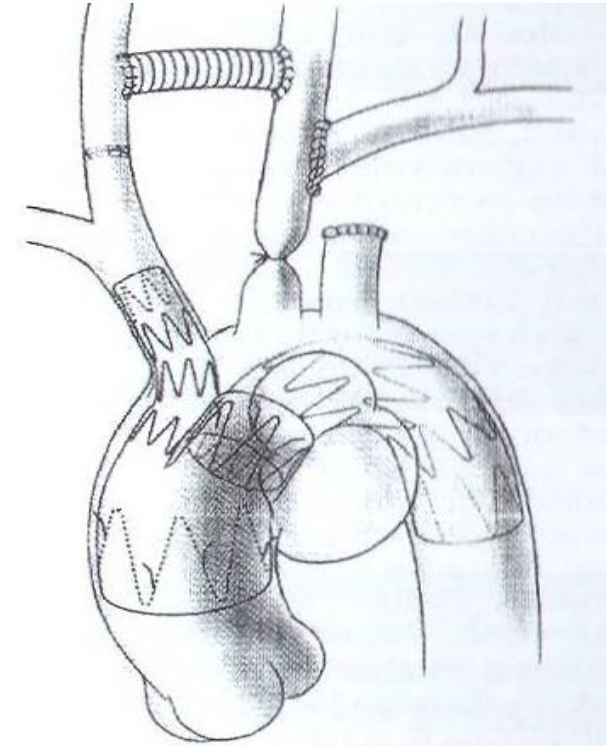

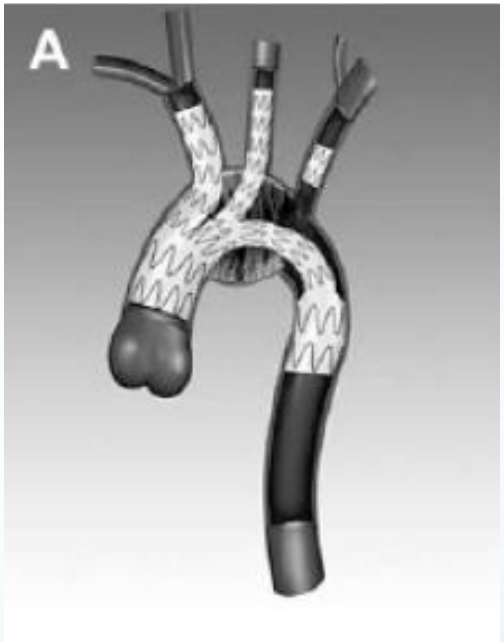

Chuter TA, *et all* ,Modular branched stent graft for endovascularrepair of aortic arch aneurysm and dissection.*J Vasc Surg.* 2003;38:859-863.

Chuter TA, Schneider DB. Endovascular Repair of the Aortic Arch *Perspect Vasc Surg Endovasc Ther* 2007; 19; 188

MODULAR BRANCHED

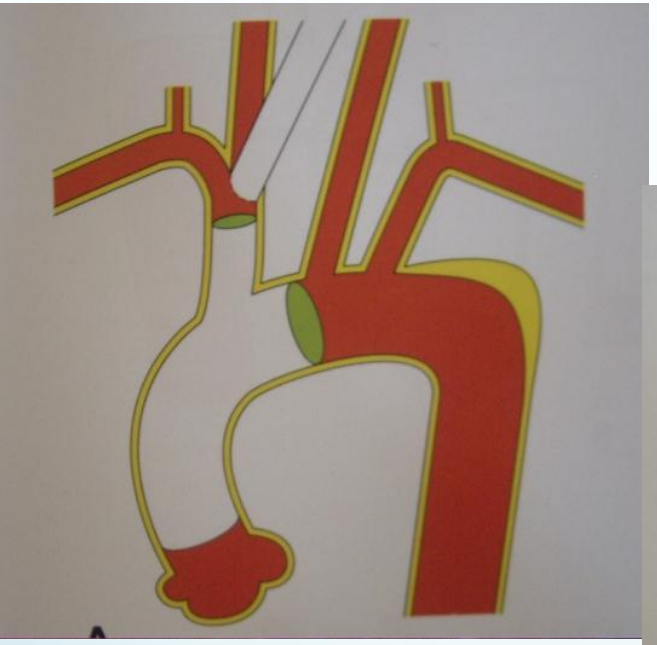

MODULAR BRANCHED

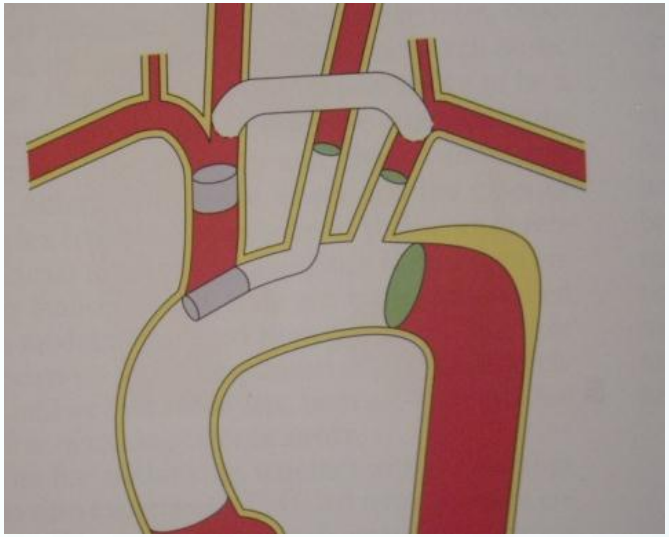

DOUBLE-BARRELL TECHNIQUE

Ann Vasc Surg. 2008 Nov;22(6):703-9. Epub 2008 Aug 5.
Double-barrel technique for preservation of aortic arch branches during thoracic endovascular aortic repair.
Baldwin ZK, Chuter TA, Hiramoto JS, Reilly LM, Schneider DB.

. Vol. 22, No. 6, 2008 *Double-barrel techni*

The technique uses commercially available devices and permits complete aortic arch coverage (zone 0) without a sternotomy. Initial outcomes are encouraging, long-term durability remains unknown.

CHIMNEY

J Cardiovasc Surg (Torino). 2009 Aug;50(4):475-81.
The applicability of chimney grafts in the aortic arch.

Sugiura K, Sonesson B, Akesson M, Björses K, Holst J, Malina M.

Chimney grafts in the supra-aortic branches seem feasible and may facilitate urgent TEVAR in patients with an inadequate proximal neck



BRANCHED

[J Vasc Surg. **2005]**
Inoue K *et al*
Feasibility of the Inoue **single-branched stent-graft implantation** for thoracic aortic aneurysm or dissection involving the left subclavian artery: short- to medium-term results in 17 patients.

Circulation. **1999**;100(19 suppll316-ll321
Inoue K, *et al*.
Aortic arch reconstruction by transluminally placed endovascular branchedstent graft.

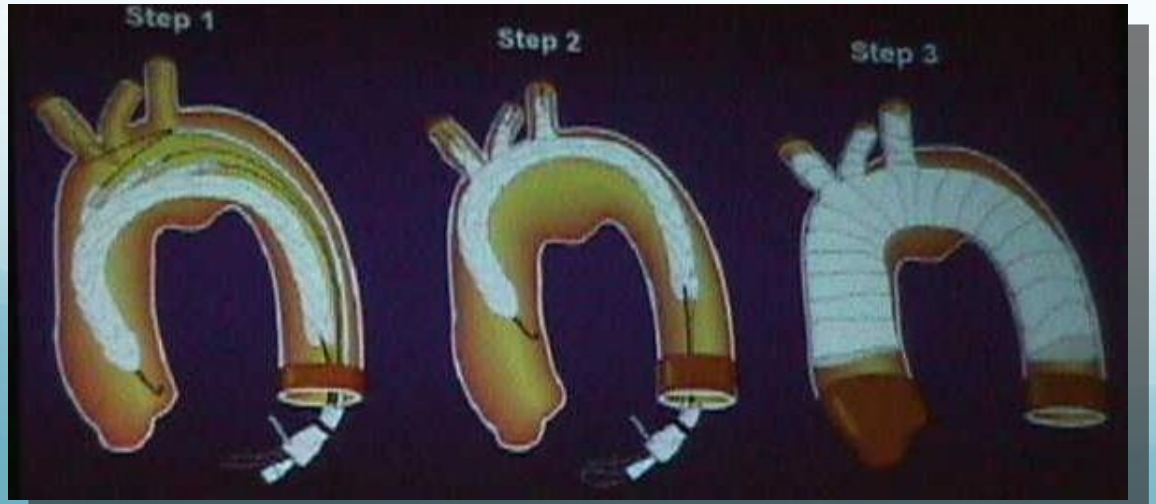

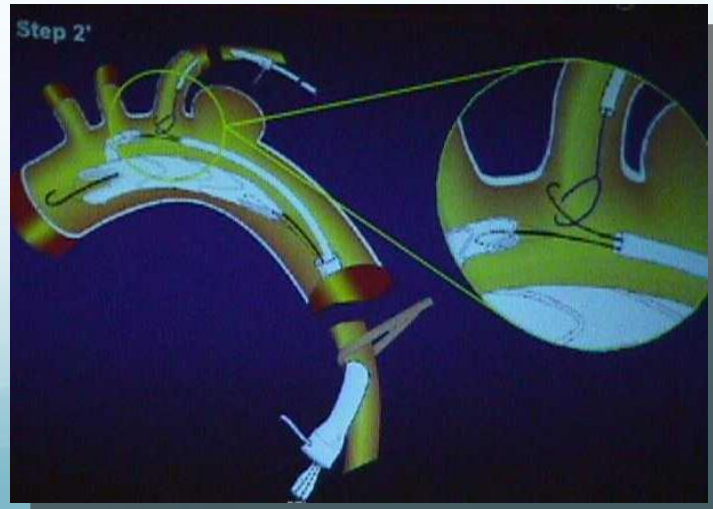

BRANCHED

GORE



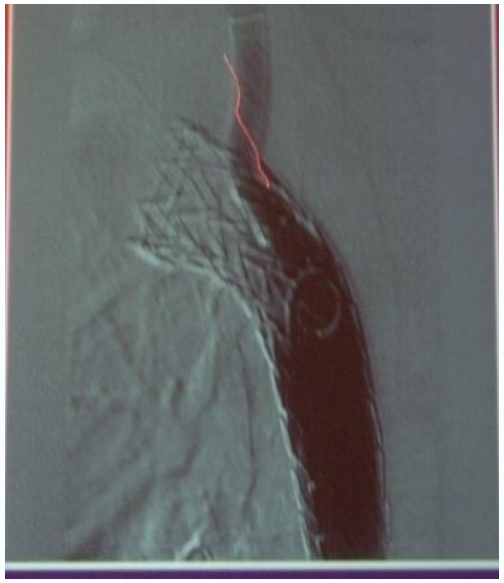

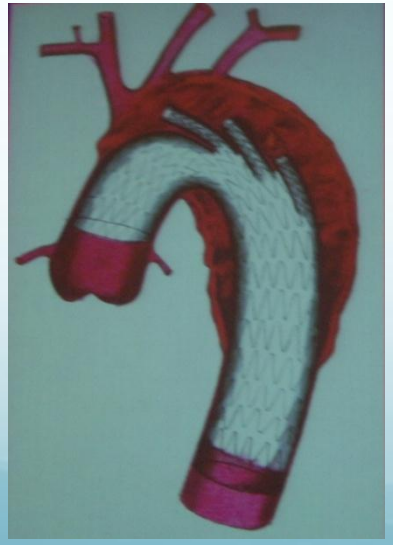

New Branched Graft Device from COOK to Recostruct Aortic Anuerysm

Krassi Ivancev VEITH 2011

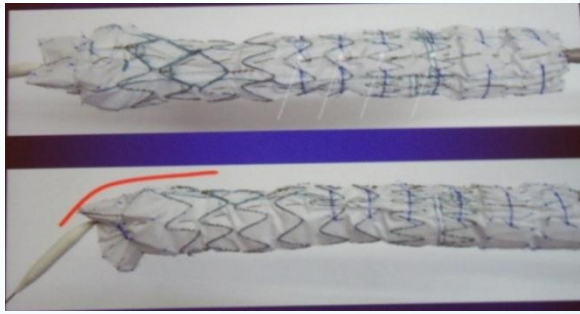

SOME DISADVANTAGES OF THE CUSTOM MADE DEVICES:

delay in device manufacturing,
anatomical and technical challenges,
high degree of planning,
cost hinder

IN-SITU FENESTRATION of HEMI AORTIC ARCH

MM *J Endovasc Ther. 2003;10:946-952*.
Retrograde fenestration of endoluminal grafts from target vessels: feasibility, technique, and potential usage.

McWilliams RG, Fearn SJ, Harris PL, Hartley D, Semmens JB, Lawrence-Brown MM

J Endovasc Ther. 2004;11:170-174
In situ stent-graft fenestration to preserve the left subclavian artery.

McWilliams RG, Murphy M, Hartley D, Lawrence-Brown MM, Harris PL

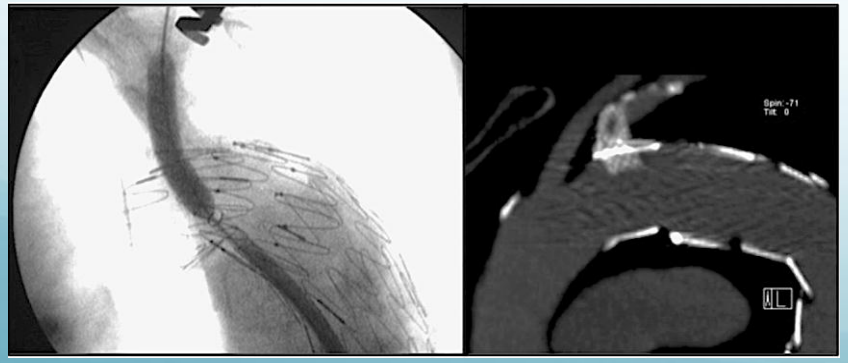

J ENDOVASC THER 2009;16:457–463

Endovascular Repair of Acute Traumatic Thoracic Aortic Transsection With Laser-Assisted In-Situ Fenestration of Stent-Graft Covering the Left Subclavian Artery

Erin H. Murphy, J. Michael Dimaio, William Dean, Michael E. Jessen and Frank R. Arko.

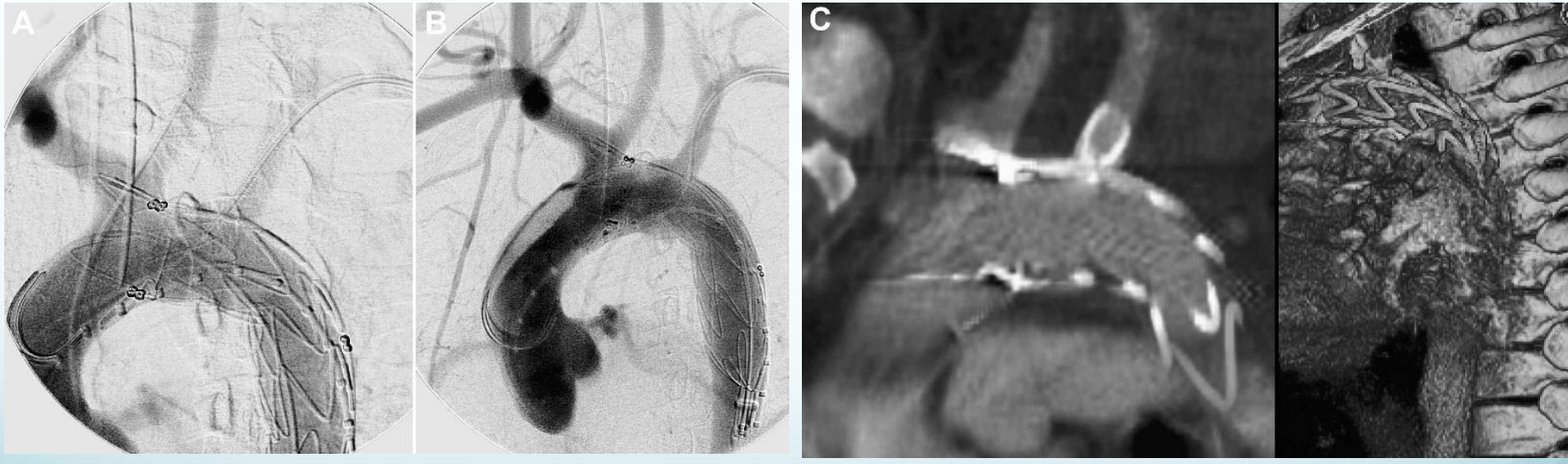

Turbo Elite laser ablation catheter,Spectranetics, Colorado Springs, CO

J Vasc Surg. 2010;52:491-494.

In situ fenestration in the aortic arch

Manning BJ, Ivancev K, Harris PL.

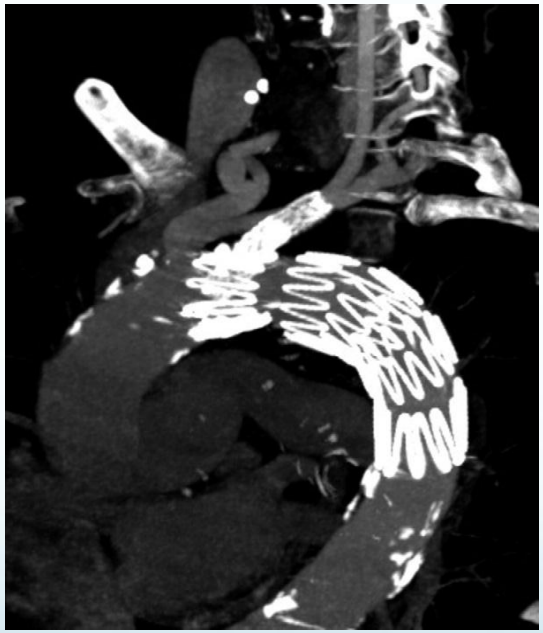

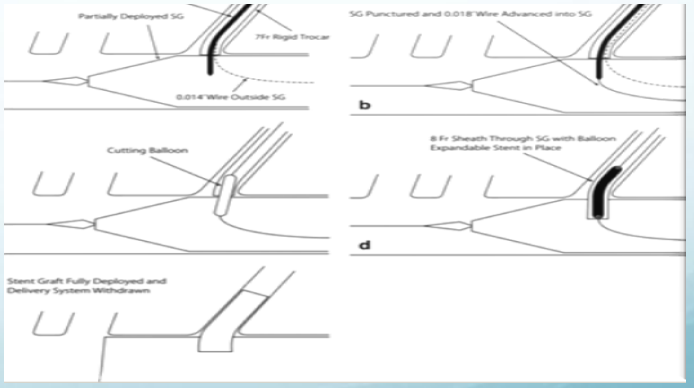

J Endovasc Ther. 2012 Apr;19(2):226-30.

In situ laser fenestration for revascularization of the left subclavian artery during emergent thoracic endovascular aortic repair.

Ahanchi SS, Almaroof B, Stout CL, Panneton JM.

Laser fenestration was successful in 5 of 6 attempts;. There were no fenestration-related complications and no neurological morbidity. At a mean 8-month follow-up (range 1-17), no patients had died, and all LSA stents were patent, with no fenestration-related endoleaks on imaging.

In situ retrograde laser fenestration is a feasible and effective option for revascularizing the LSA during emergent TEVAR. Longer follow-up is necessary to determine the durability of this technique.

Revascularization of LSA:

Decrease in overall stroke rate from 6.4 to 2.3%
Posterior circulation stroke from 5.5 to 1.2%

10% of patients should have work-up of Cerebral arteries

left Vertebral artery dominancy
left Vertebral artery origin from arcus aorta

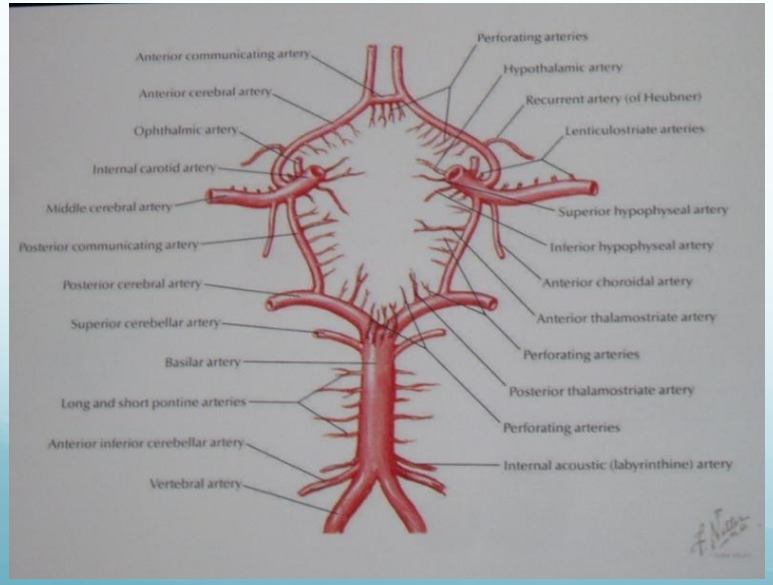

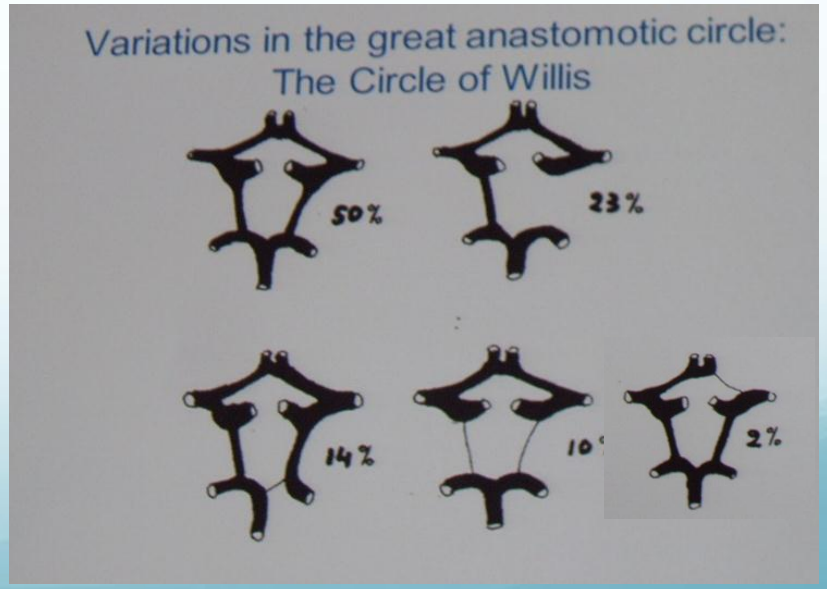

Interact Cardiovasc Thorac Surg. 2008 Aug;7(4):535-8

Endovascular aortic arch reconstruction via fenestration in situ with cerebral circulatory support: an acute experimental study

Numan F, Arbatli H, Bruszewski W.Cikirikcioglu M.

Ann Vasc Surg. 2010 Apr;24(3):419-22

Dynamic human cadaver model for testing the feasibility of new endovascular techniques and tools

Arbatli H, Cikirikcioglu M, Pektok E, Walpoth BH, Fasel J, Kalangos A, Bruszewski W, Numan F.

CEREBRAL PROTECTION

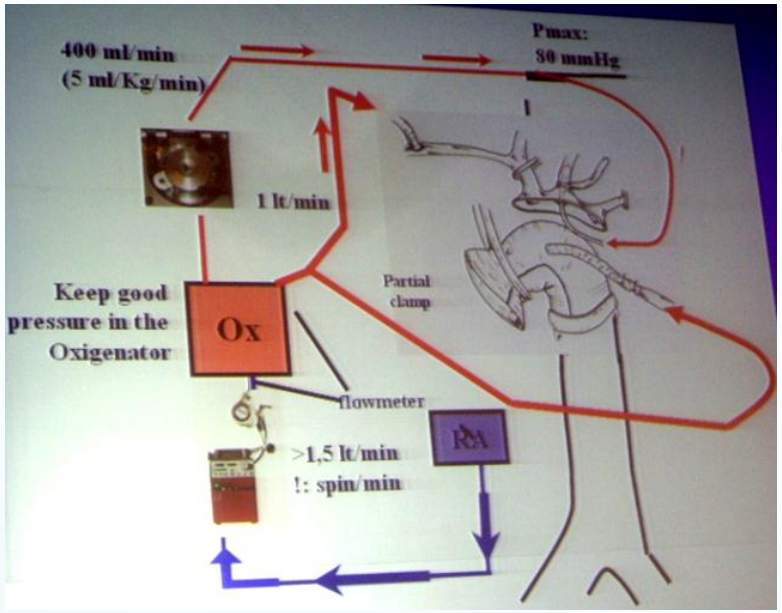

Open Surgery

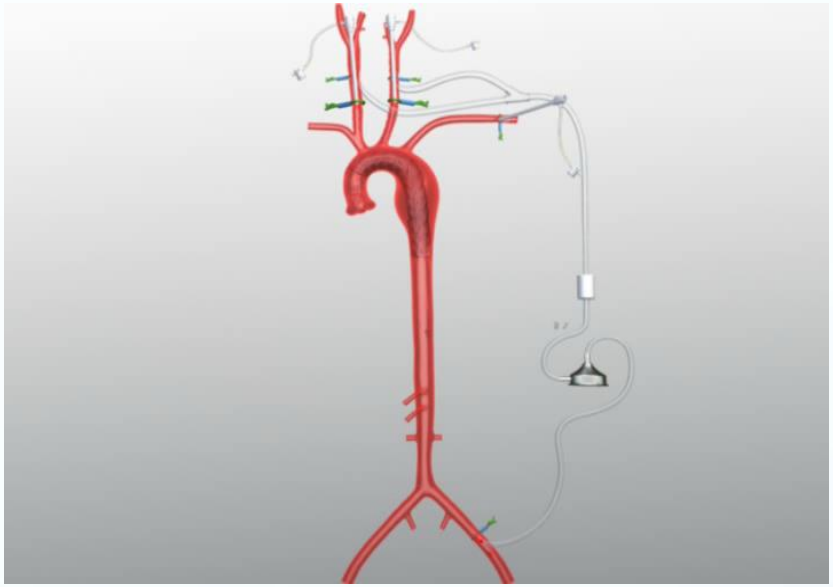

Temporary L Femoral-bicarotid
L axillary bypass

Total endovascular aortic arch reconstruction via fenestration in situ with cerebral circulatory support: an acute experimental study,

Numan F, Arbatli H, Bruszewski W.Cikirikcioglu M.
Interact Cardiovasc Thorac Surg. 2008 Aug;7(4):535-8

IN SITU FENESTRATION TECHNIQUE

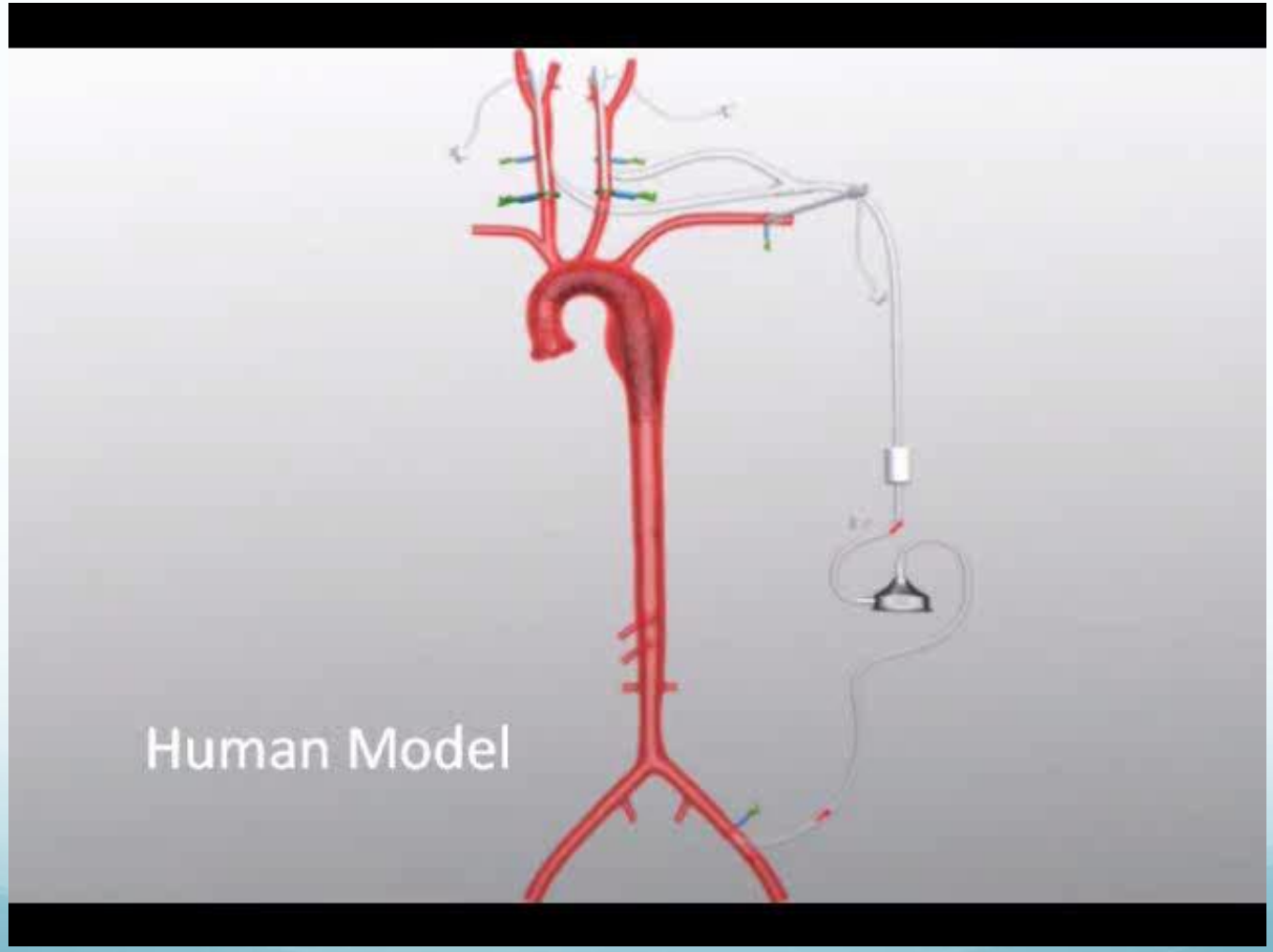

ACUTE

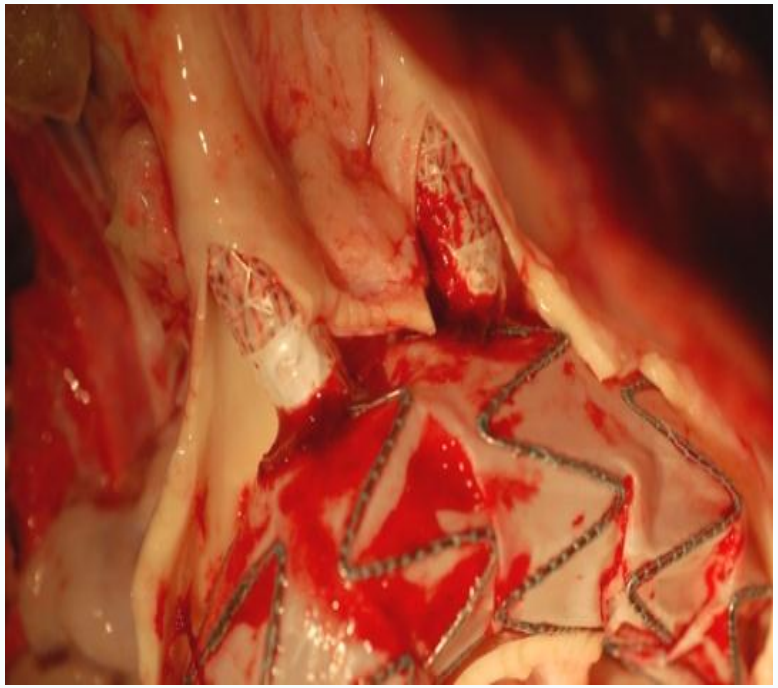

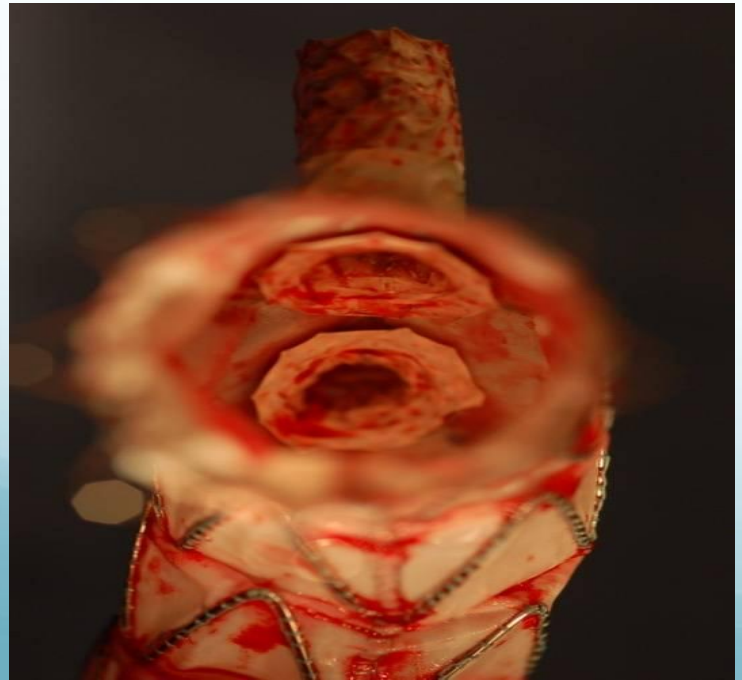

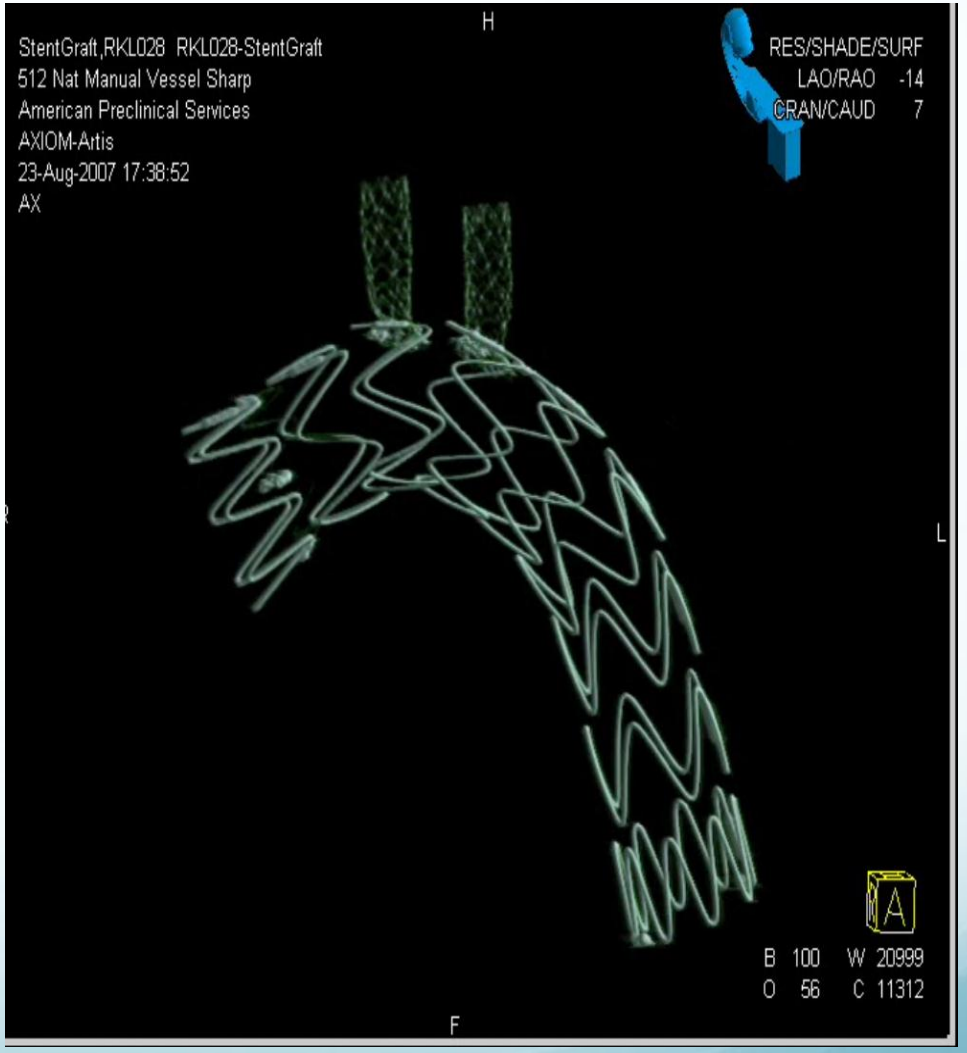

ENDOSKELETON

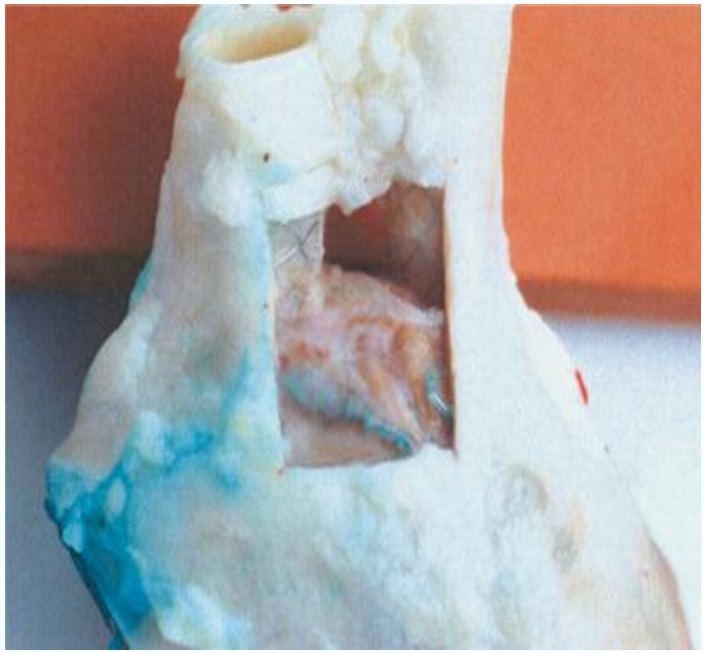

CHRONIC



Endovascular total aortic arch replacement by in situ stent graft fenestration technique.

Sonesson B, Resch T Allers M, Malina M.
Vascular Center Malmö-Lund, Malmö University Hospital, Malmö, Sweden.2009

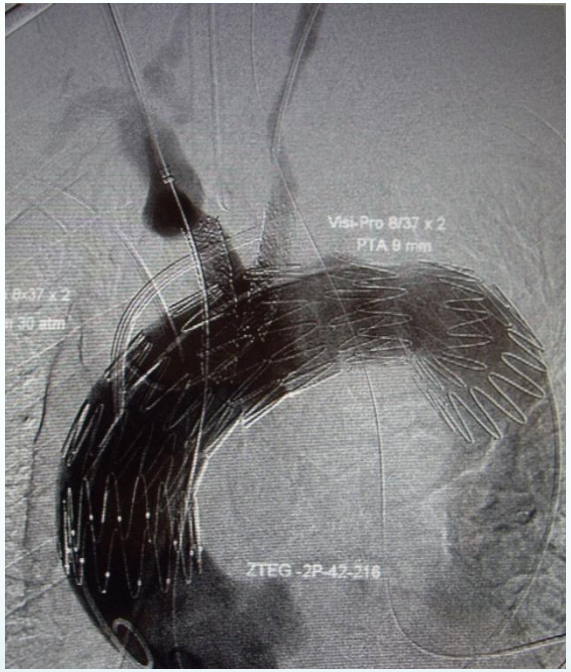



a temporary bypass from the left femoral artery to both carotids

Laser fenestration and Talent stent graft

J Vasc Surg. 2012 Aug 1. [Epub ahead of print]

New temporary internal introducer shunt for brain perfusion during total endovascular arch replacement with in situ fenestration technique.

Sonesson B, Resch T, Dias N, Malina M.

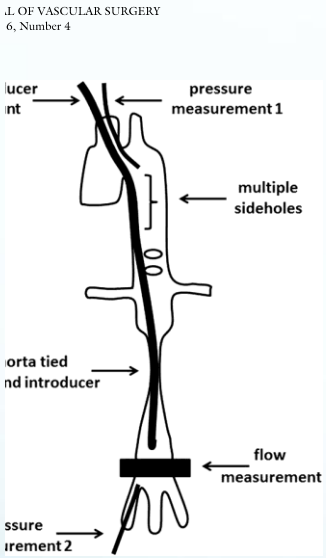

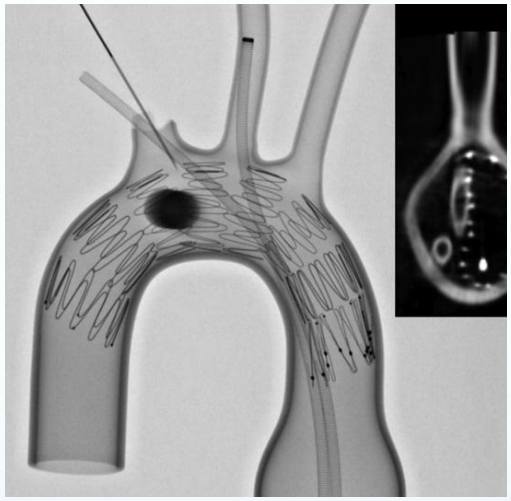

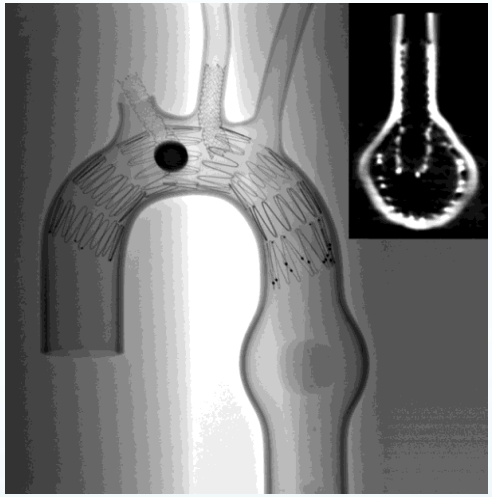

This technique represents an adjunctive step toward a complete endovascular repair for the aortic arch.

Yes, in situ fenestration of aortic stent grafts is an attractive alternative to widen the therapeutic options and to offer a patient-tailor solution ,

and

today we are more close to reconstruct the aortic arch than yesterday.