Bovine Aortic Arch – Not a Benign Variant

2nd International Meeting on Aortic Diseases
Liege, Belgium
September , 2010

John A. Elefteriades, MD
William W.L. Glenn Professor and Chief,
Section of Cardiac Surgery
Yale University School of Medicine

Beating a Sudden Killer

When a young woman nearly died from a ruptured aneurysm, the author and the woman's husband began searching for ways to save other aneurysm patients from catastrophe

BY JOHN A. ELEFTERIADES

It was the first beautiful Saturday in spring, and I was in

Aneurysms Largely Asymptomatic

- Vast majority of patients with TAA (90-95%) have no sx until rupture/dissection occur.[1,2]
- First symptom is usually death from rupture or dissection.
- Urgent need for screening tests.

1. Barrat-Boyes BG. Lancet 1957:716-720.
2. Elefteriades JA et al. Diseases of the Aorta. Hurst's The Heart. McGraw-Hill. New York. 2008.

"Bovine Arch" Anatomy

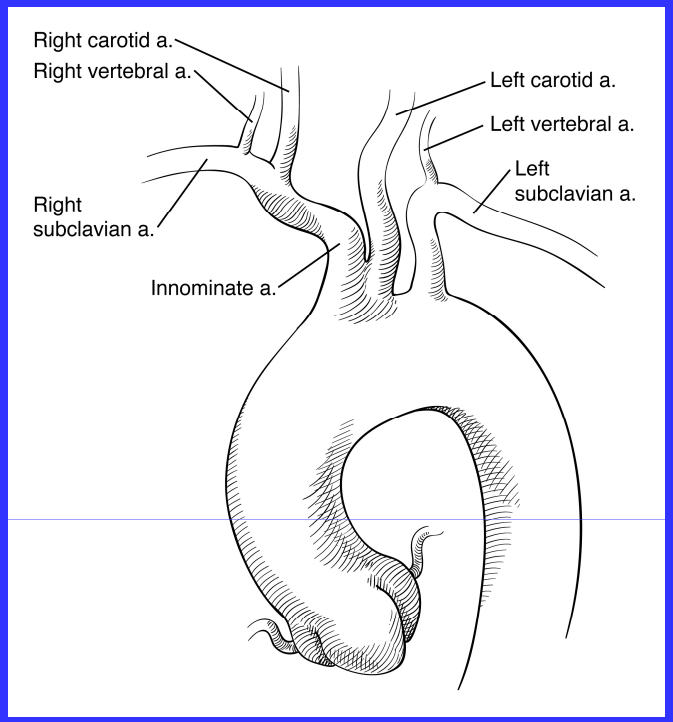

Common origin of innominate artery and left common carotid artery (most common)[1]

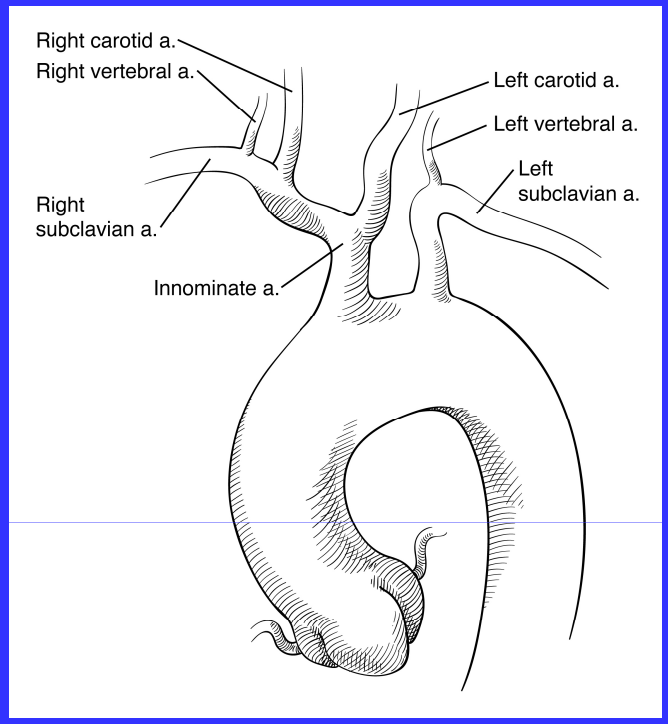

Left common carotid artery originates from innominate artery at distance from aorta (less common)[1]

* Note that **bovine arch is a misnomer** – the cow's aorta does not resemble either of these configurations.[2]

1. Lippert H, Pabst R. Arterial Variations in Man: Classification and Frequency. München: J.F. Bergmann Verlag, 1985.
2. Layton KF, Kallmes DF, Cloft HJ, Lindell EP, Cox VS. Bovine aortic arch variant in humans: clarification of a common misnomer. AJNR *Am J Neuroradiol* 2006;27:1541-1542.

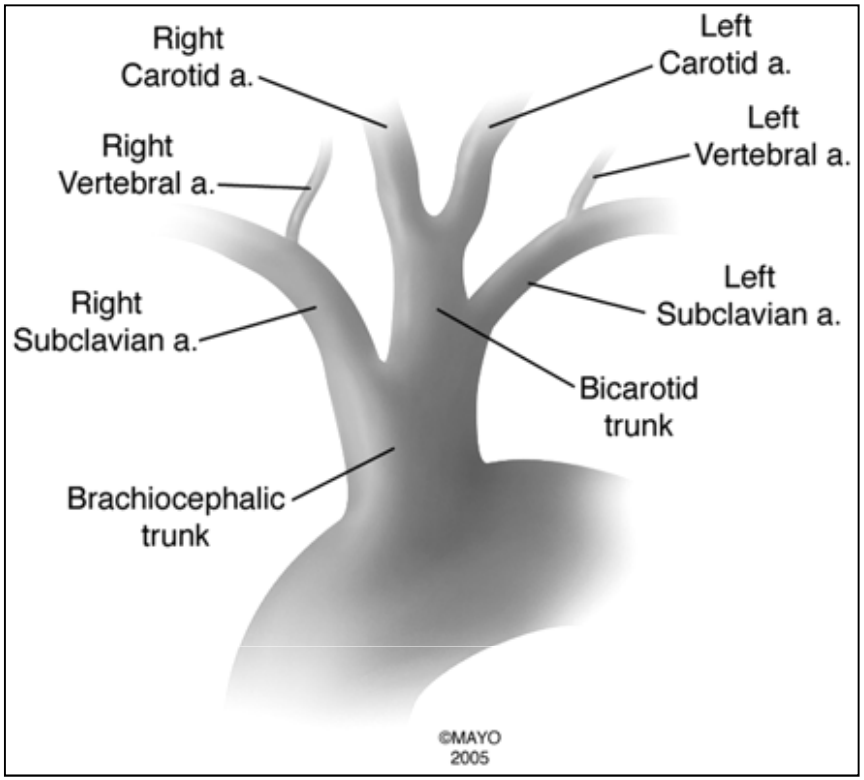
Right
Carotid a.
Left
Carotid a.
Right
Vertebral a.
Left
Vertebral a.
Right
Subclavian a.
Left
Subclavian a.
Bicarotid
trunk
Brachiocephalic
trunk
©MAYO
2005



Study Aims

- Bovine arch traditionally viewed as "normal," clinically insignificant variant
- We have noted in OR that bovine arch is common in patients with thoracic aortic aneurysm (TAA)

We wish to better define any association between bovine arch and thoracic aortic disease

Patient Population

- Disease group: 383 pts w/ known TAA and thoracic CT or MRI scan on record

- Control group: 350 pts without aortic disease, randomly selected from all patients who underwent thoracic CT scan at YNHH

Methods

- Retrospective review of CT/MRI for presence of bovine arch
- Review of imaging reports for citation of bovine arch by original radiologist
- Disease group: asses
  - TAA diameter
  - presence of bicuspid aortic valve
  - clinical outcomes (dissection, rupture, repair)

Bovine Arch on Thoracic Imaging

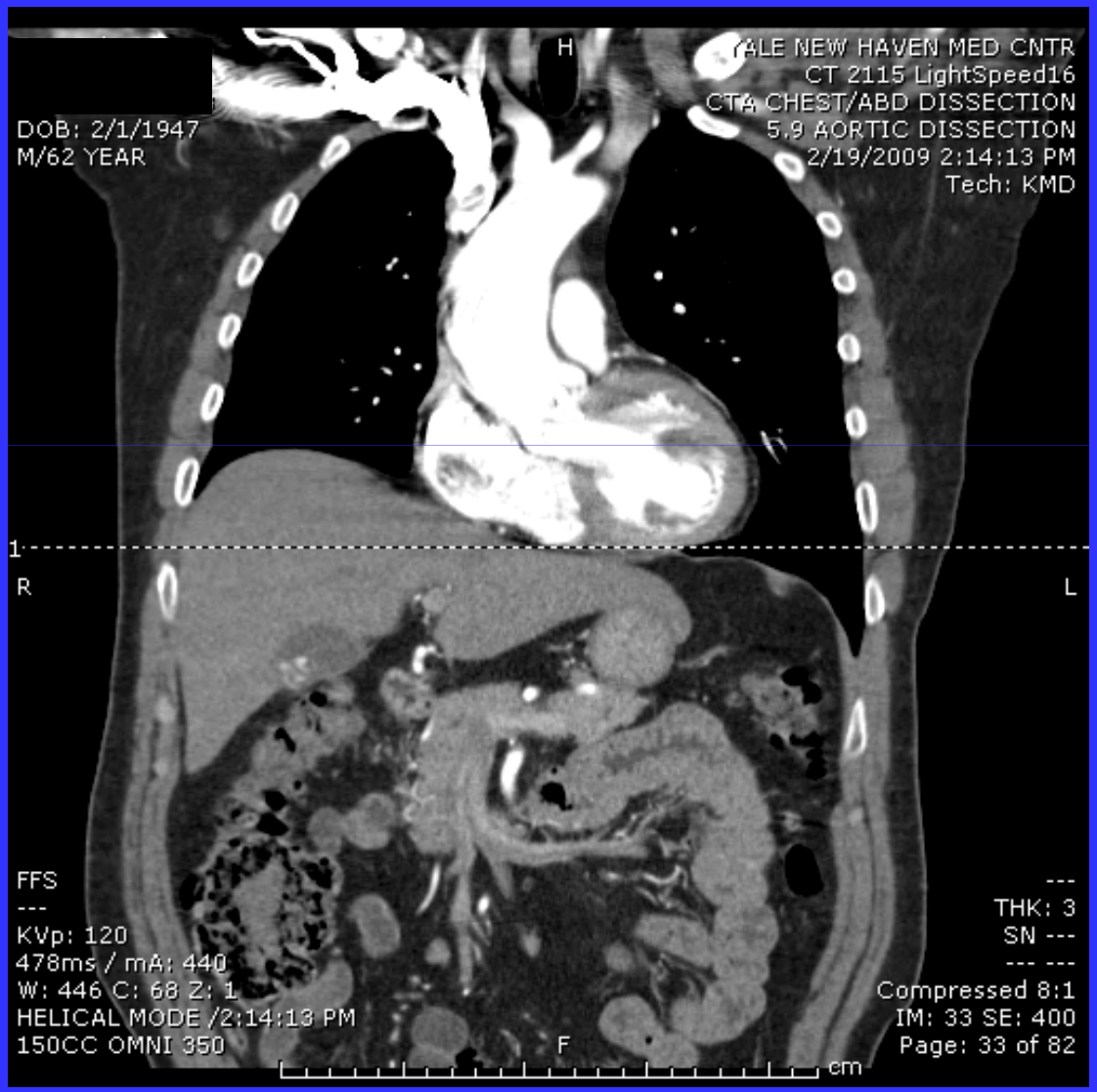

Bovine Arch on Thoracic Imaging

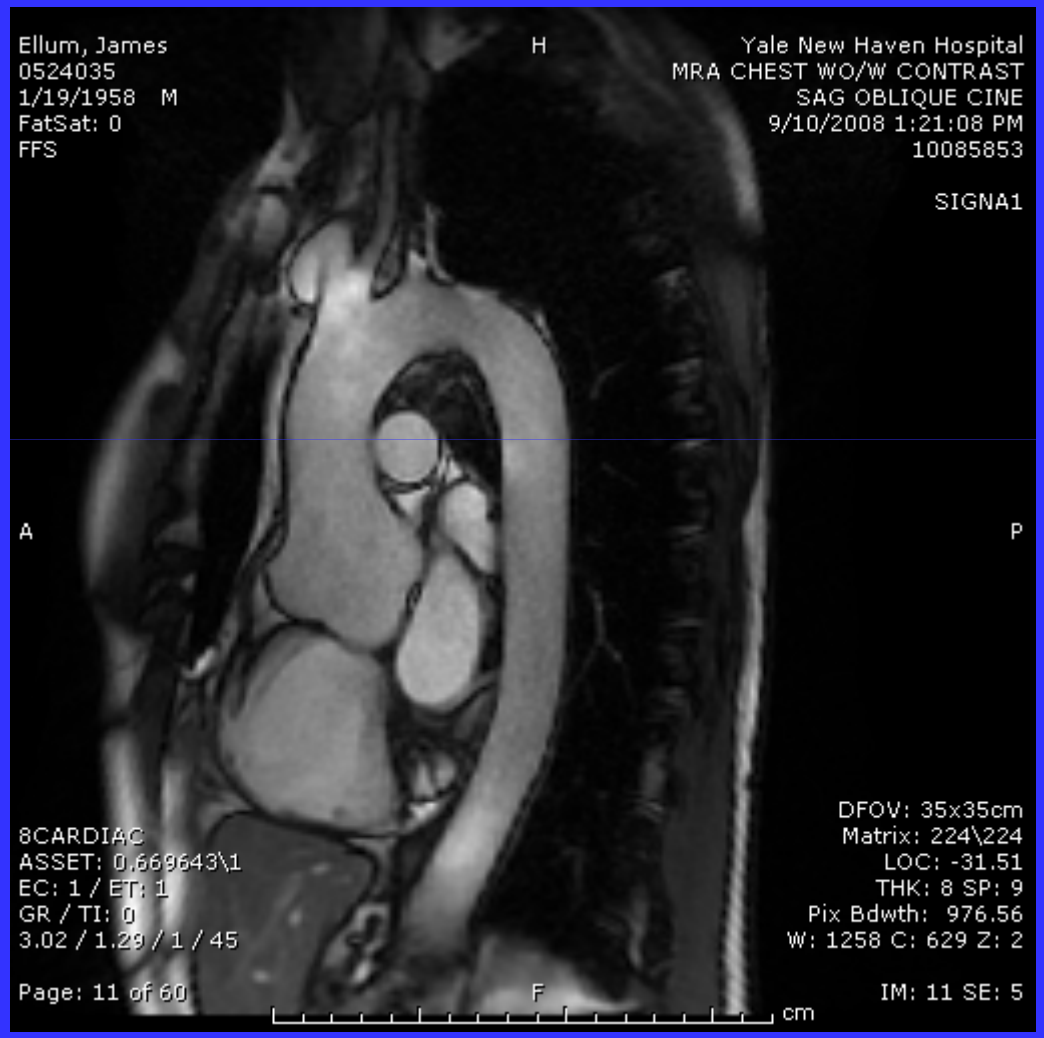

Results: Incidence of Bovine Arch

Variable	TA Disease Group	Control Group	P value
Total number	383	350	
Total BA+ (%)	99 (25.8%)	31 (8.9%)	<0.001

- Imaging reports (radiologists) cited bovine arch in only 11 of 99 (11%) of patients deemed BA+ by our group

- Incidence of bovine arch significantly greater in patients with thoracic aortic disease than in patients without disease

Incidence of BA in Thoracic Aortic Disease and Control Groups

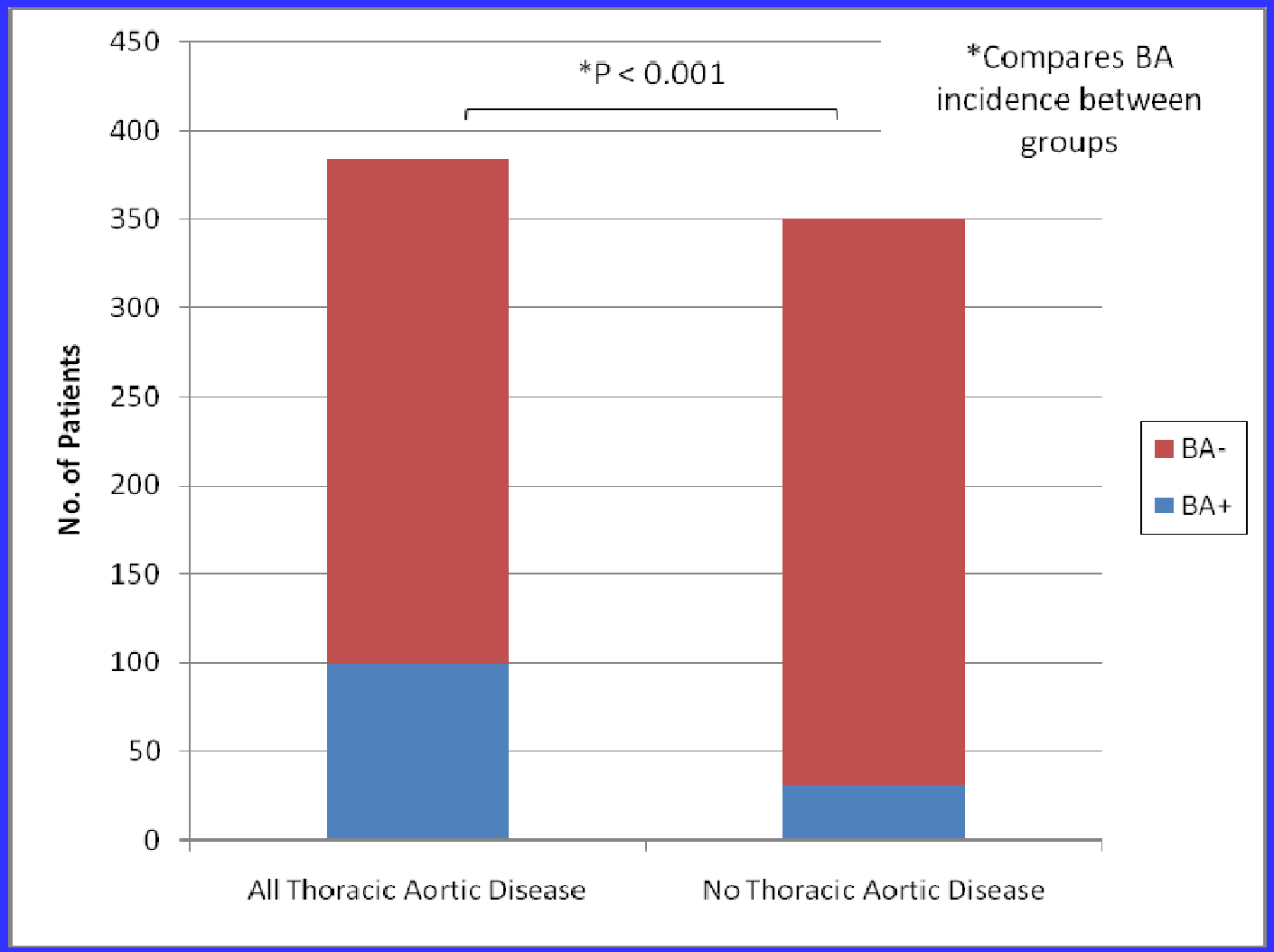

Bovine Arch and TAA Growth Rate (cm/year)

Variable	All Yale patients [3]	BA- (n=107)	BA+ (n=40)	P value (BA- vs. BA+)
All Thoracic Aortic Disease	**0.10**	**0.10**	**0.30**	**0.02**
Chronic Dissection	0.31	0.21	0.44	0.04
No Dissection	0.05	0.08	0.23	0.16
Ascending/Arch	0.09	0.08	0.19	0.27
Descending	0.12	0.15	0.50	0.01

- TAAs grow significantly faster in patients with bovine arch than in patients without bovine arch

3. Coady MA, Rizzo JA, Elefteriades JA. Developing surgical intervention criteria for thoracic aortic aneurysms. *Cardiol Clin* 1999;17:827-839.

BA not significantly associated with:

- Thoracic aortic dissection
- Location of thoracic aortic disease (ascending, arch, descending)
- Age at discovery of thoracic aortic disease
- Bicuspid aortic valve
- Gender

Conclusions

1) Radiology reports often overlook bovine arch.
2) Bovine aortic arch is significantly more common in patients with TAA than in the general population.
3) Aortas in bovine arch patients grow faster than general TAAs.
4) These observations argue strongly that bovine arch should <u>not</u> be considered a normal variant of aortic arch anatomy.

Recommendations

1) Radiologists must consistently look for and report bovine arch anatomy on thoracic scans.
2) Since “bovine arch” is a misnomer, we propose the name “common origin aortic arch” to describe this group of anatomic variants.
3) Patients with bovine arch should be followed for TAA.

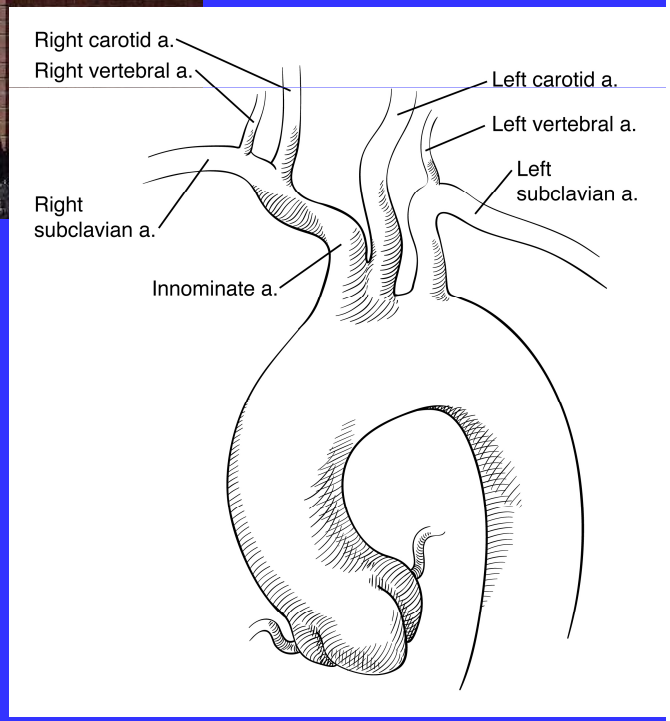

Bovine arch anatomy on a routine CT scan can help us identify hidden patients with TAA.